

Access this article online
Quick Response Code:

Website: www.joas.in
DOI: 10.4103/joas.joas_33_18

Tuberculosis presenting as a scaphoid fracture: A rare case report

Ganesh Singh Dharmshaktu, Tanuja Pangtey¹

Abstract:

Tuberculosis of the wrist is an uncommon clinical entity and mostly presents as insidious pain and swelling. Presentation of singular carpal bone involvement is rare as the presenting feature. A case of scaphoid fracture was evaluated in a 20-year-old male patient, and underlying tuberculosis was diagnosed on magnetic resonance imaging and culture of joint fluid. Antitubercular therapy under appropriate supervision resulted in clinical improvement and optimal regain of function. No reactivation of the disease was noted in a follow-up of 2 years. This case highlights a rare presentation of tuberculosis presenting with a fracture of scaphoid.

Keywords:

Carpal, fracture, scaphoid, tuberculosis, wrist

Introduction

Wrist joint is an uncommon location for osteoarticular tuberculosis with reported incidence of <1% of all skeletal tuberculosis cases.^[1] Initially, synovial or joint capsule involvement is found, which may later affect the entire joint with synovial hypertrophy and bone erosions. Radiographs may reveal joint-space narrowing, eccentric lesion, and juxtaarticular osteoporosis as the usual features. Pathological fracture of isolated carpal bone like scaphoid is a rare event and may delay the diagnosis in the absence of constitutional features.

Case Report

A 20-year-old male patient was brought to us for left wrist pain for 3 months that was increasing for the last 2 weeks, and the radiographs revealed fracture of scaphoid waist region without associated bony injuries. He was given plaster splints for a total period of 6 weeks following which the radiograph revealed the presence of fracture gap without union [Figure 1]. The pain and

swelling were found to be increased with limitation of range of motion. The magnetic resonance imaging (MRI) was advised and evaluated to reveal marrow edema in scaphoid with fracture through the waist area. A few cystic changes were noted near the irregular fracture line. The entire scaphoid was seen with altered signals with hypointense in T1 and hyperintense in T2 and fat-suppression images. There was extensive surrounding soft-tissue edema with synovial proliferation around the scaphoid, and a probable diagnosis of infective etiology was suspected [Figures 2 and 3]. The wrist joint was aspirated under fluoroscopic guidance, and the aspirate was sent for culture and sensitivity, Gram stain, stain for acid-fast bacilli, and polymerase chain reaction (PCR) for tuberculosis. The culture was positive for *Mycobacterium tuberculosis*. Appropriate body weight-related four-drug antitubercular treatment was initiated following relevant baseline blood investigations. A marked improvement was noted after 5 weeks of therapy that was continued till 18 months as per the institutional protocol with staged conversion to three- and two-drug regimen. Pain and swelling were decreased, and the range of motion was also improved leading

This is an open access journal, and articles are distributed under the terms of the Creative Commons Attribution-NonCommercial-ShareAlike 4.0 License, which allows others to remix, tweak, and build upon the work non-commercially, as long as appropriate credit is given and the new creations are licensed under the identical terms.

For reprints contact: reprints@medknow.com

How to cite this article: Dharmshaktu GS, Pangtey T. Tuberculosis presenting as a scaphoid fracture: A rare case report. J Orthop Allied Sci 2019;7:31-3.

Departments of
Orthopaedics and
Pathology, Government
Medical College,
Haldwani, Uttarakhand,
India

Address for correspondence:

Dr. Ganesh Singh
Dharmshaktu,
Department of
Orthopaedics, Government
Medical College,
Haldwani - 263 139,
Uttarakhand, India.
E-mail: drganeshortho@
gmail.com

to improved activities of daily living. Radiograph at the end of therapy, however, showed ankylosis between carpals and almost pancarpal ankylosis while clinical profile was dramatically improved.

Discussion

Isolated scaphoid involvement is rare in tuberculosis and even is not described in large series of wrist tuberculosis of 32 cases.^[2] We could gather only six reported cases of isolated scaphoid affliction out of several with wrist monoarthritis or with multiple carpal and tenosynovial involvement. Of the reported cases with scaphoid involvement, the fracture at initial presentation is described in just one case.^[3] In an another case, scaphoid cortical breach was appreciated only in the MRI and cases of tubercular scaphoid involvement (diagnosed

with or without MRI) that were later confirmed by histopathological examination or PCR are very few.^[3-7] One case of scapholunate ligament has been described, along with extensor tenosynovitis, without any involvement of scaphoid and that we have also included in the list [Table 1]. This case snippet highlights the importance of careful evaluation of seemingly common clinical entities to rule out significant underlying pathology by clinical and judicious investigative means.

Conclusion

The uncommon presentation of common problems in the endemic region should be acknowledged and anticipated. Fractures with conspicuous features, at times, require further evaluation to rule out sinister underlying pathology. A careful history,

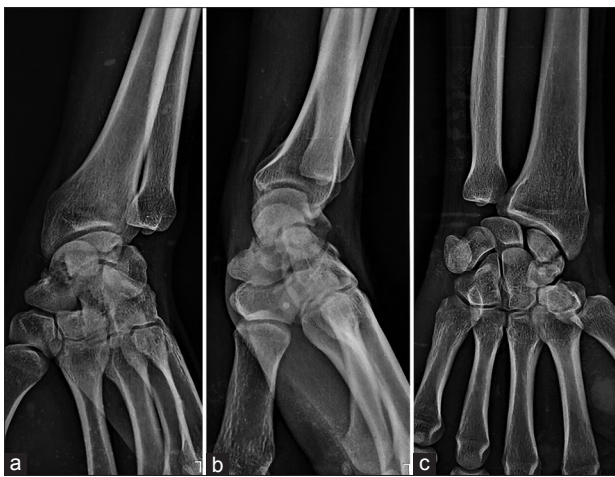


Figure 1: The radiograph showing fracture of scaphoid in oblique (a) and two orthogonal views (b and c). There is, however, area of cystic lucency surrounding fracture line and the rest of the bones appear normal

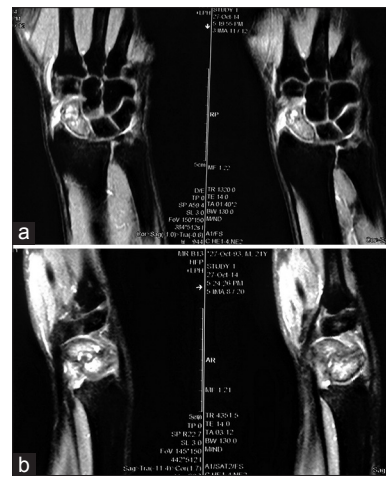


Figure 2: The magnetic resonance imaging showing marrow edema and destruction of scaphoid and surrounding extensive soft-tissue edema in T1 coronal (a) and sagittal views (b)

Table 1: Cases describing isolated scaphoid and scapholunate region tuberculosis (2011 onward)

Author/years	Age/sex	Presentation, duration, and laterality	Radiograph features	MRI	Diagnosis
Mishra and Gupta (2011) ^[3]	22/male	Pain and swelling, 6 months, right	Fracture scaphoid	-	PCR of synovial fluid
Siddiqui <i>et al.</i> (2012) ^[4]	42/male	Pain and decreased motion, 2 months, right	Osteolytic lesion on the second radiograph, CT scan showing sequestra and mild periosteal reaction	-	Debridement and sample, HPE
Vyavan <i>et al.</i> (2014) ^[5]	79/male	Pain and swelling, right	Resorption of proximal pole scaphoid	Involvement of all carpal bones except pisiform	Biopsy from scaphoid bone and HPE
Prakash and Mehtani (2015) ^[6]	12/female	Chronic painful swelling, 7 months, left	Lytic lesion distal pole with sclerotic rim	Lytic lesion, lateral cortical break	Image-guided core biopsy by the Jamshidi needle and HPE
Naveen and Gokul (2015) ^[7]	79/male	Pain and swelling, 2 months, right	Atrophic resorption of scaphoid	-	HPE
Sbai <i>et al.</i> (2015) ^[8]	58/female	Pain and swelling, 3 months, left	Lytic proximal scaphoid	Scapholunate lesion and extensor tenosynovitis	HPE
Our case	20/male	Pain and swelling, 3 months and increasing by 2 weeks, left	Fracture with cystic lucencies along fracture line	Edema of scaphoid and destruction	PCR of synovial fluid

CT=Computerized tomography, PCR=Polymerized chain reaction test, HPE=Histopathological examination, MRI=Magnetic resonance imaging

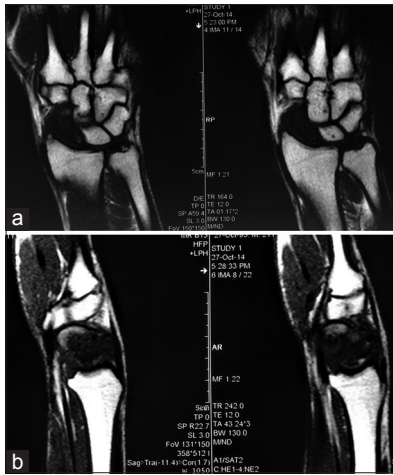

Figure 3: The same lesion is hypointense in fat-suppressed coronal (a) and sagittal T1 view showing the altered signal and destruction of scaphoid (b)

clinical assessment, and judicious use of imaging are critical to timely diagnosis followed by appropriate treatment.

Declaration of patient consent

The authors certify that they have obtained all appropriate patient consent forms. In the form the patient(s) has/have given his/her/their consent for his/her/their images and other clinical information to be reported in the journal. The patients understand

that their names and initials will not be published and due efforts will be made to conceal their identity, but anonymity cannot be guaranteed.

Financial support and sponsorship

Nil.

Conflicts of interest

There are no conflicts of interest.

References

1. Tuli SM. Tuberculosis of the Skeletal System (Bones, Joints, Spine and Bursal Sheaths). 3rd ed. New Delhi: Jaypee Brothers; 2004.
2. Kotwal PP, Khan SA. Tuberculosis of the hand: Clinical presentation and functional outcome in 32 patients. *J Bone Joint Surg Br* 2009;91:1054-7.
3. Mishra D, Gupta A. Tuberculosis of wrist presenting as scaphoid fracture: A case report. *Malaysian Orthop J* 2011;5:47-9.
4. Siddiqui MA, Ali Rizvi SW, Ali Rizvi SA. Isolated tubercular scaphoid osteomyelitis: A case report. *Orthop Surg* 2012;4:64-6.
5. Vyravan PR, Radhakrishnan P, D'Cruise L, Faisal J, Rajappa S, Menon G. Scaphoid tuberculosis difficulties of diagnosis. *IOSR J Dent Med Sci* 2014;13:44-5.
6. Prakash J, Mehtani A. Isolated tuberculosis of scaphoid in the skeletally immature: A rare cause of chronic wrist pain. *BMJ Case Rep* 2015;2015. pii: bcr2015209569.
7. Naveen L, Gokul R. Pathological resorption of the scaphoid: A rare presentation of the TB wrist. *J Clin Orthop Trauma* 2015;6:77.
8. Sbai MA, Benzarti S, Bouzaidi K, Sbei F, Maalla R. A rare localization of tuberculosis of the wrist: The scapholunate joint. *Int J Mycobacteriol* 2015;4:161-4.