

Access this article online

Quick Response Code:



Website:

www.joas.org.in

DOI:

10.4103/joas.joas\_36\_19

# Noncontiguous two levels traumatic dislocation of the cervical spine managed with a posterior only approach

Amit Agrawal, V. A. Kiran Kumar, N. A. Sai Kiran, M. Venkatesh<sup>1</sup>, V. Anil Kumar

## Abstract:

Literature defines multiple noncontiguous vertebral injuries, as “injuries to the vertebral column involving  $\geq 1$  site, and these injuries are separated by an apparently normal area of the spine.” In the present article, we report an unusual case of two nonadjacent levels traumatic dislocation, involving the cervical spine managed through the posterior-only approach.

## Keywords:

Cervical spine fractures, noncontiguous spine fracture, posterior approach, spinal injuries

## Introduction

Literature defines multiple noncontiguous vertebral injuries, as “injuries to the vertebral column involving  $\geq 1$  site, and these injuries are separated by an apparently normal area of the spine.”<sup>[1]</sup> Usually, these injuries involve different spinal region, that is, thoracic/thoracolumbar or cervical in combination<sup>[1-4]</sup> or thoracic + thoracic region;<sup>[5]</sup> however, the occurrence of multiple noncontiguous vertebral injuries in the same region, in the cervical region, is not reported. In the present article, we report an unusual case of two nonadjacent levels traumatic dislocation, involving the cervical spine managed through posterior only approach.

## Case Report

A 65-year-old male patient was brought to the emergency room 12 h after the injury. He presented with the history of slip and fall while climbing down from a tree. He noticed

weakness of all the four limbs and had urinary retention, for which an indwelling urinary catheter was placed. On examination, pulse rate was 46/min, blood pressure was 110/70 mm/hg, and respiratory rate was 18/min (predominantly abdominal breathing, with a single-breath counting of eight). The patient was conscious, alert, and oriented to time place and person (GCS: E4V5M6). Pupils were bilaterally equal and reacting to light. Motor examination showed normal bulk and hypotonia in all the limbs; the power was Grade 0 with absent deep tendon superficial reflexes. He had loss of sensation below T1 dermatome. He had priapism on examination. All the laboratory investigations including coagulation profile were normal. X-ray cervical spine was suggestive of C4/C5 and C6/C7 Grade III subluxation. Magnetic resonance imaging and computed tomography of the cervical spine showed anterior subluxation of C4 vertebra over C5 and bilateral locked facets of C4/C5 vertebra, anterior subluxation of C6 vertebra over C7, and bilateral locked facets of C6/C7 vertebra. Displaced fractures of left pedicles and superior

Departments of  
Neurosurgery and  
<sup>1</sup>Radiology, Narayana  
Medical College and  
Hospital, Nellore,  
Andhra Pradesh, India

### Address for correspondence:

Dr. Amit Agrawal,  
Department of  
Neurosurgery,  
Narayana Medical  
College and Hospital,  
Chinthareddypalem,  
Nellore - 524 003,  
Andhra Pradesh, India.  
E-mail: dramitagrawal@  
gmail.com

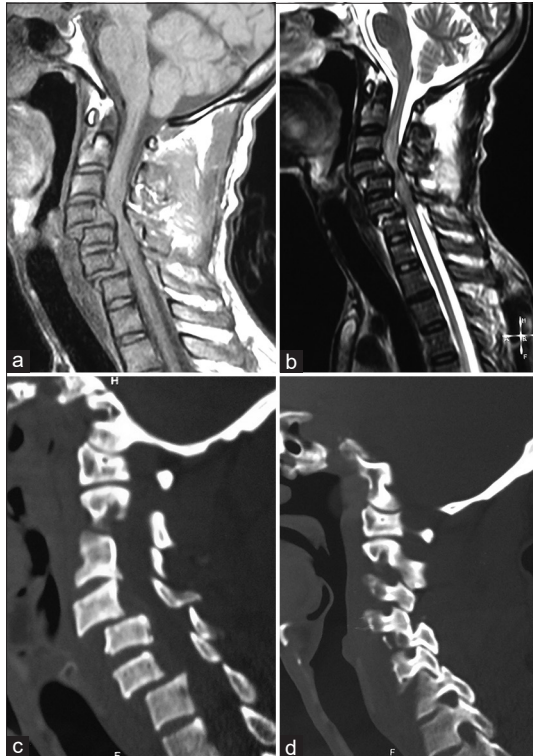
Received: 27 June 2019  
Revised: 23 August 2019  
Accepted: 14 October 2019  
Published: 13 December  
2019

This is an open access journal, and articles are distributed under the terms of the Creative Commons Attribution-NonCommercial-ShareAlike 4.0 License, which allows others to remix, tweak, and build upon the work non-commercially, as long as appropriate credit is given and the new creations are licensed under the identical terms.

For reprints contact: reprints@medknow.com

**How to cite this article:** Agrawal A, Kumar VA, Kiran NA, Venkatesh M, Kumar VA. Noncontiguous two levels traumatic dislocation of the cervical spine managed with a posterior only approach. *J Orthop Spine* 2019;7:80-2.

facets of C5 and C7 vertebra and diffuse disc edema and pseudodisc bulges of C4/C5 and C6/C7 discs were seen compressing the thecal sac and compression of spinal cord. Long-segment diffuse hyperintense signals were seen spinal cord from C2/C3 disc space to C6/C7 disc space is seen in T2W images suggestive of cord edema [Figure 1]. Ultrasonography of the abdomen did not show any abnormality. The patient was treated with Gardner–Wells Skull Tongs traction preoperatively, and the weight was increased up to 8 kg. However, there was no reduction of the subluxation. In view of the unstable general condition and highly unstable spine, the patient was planned for a posterior approach first. Accordingly, the patient was taken for surgery. The patient was placed in prone position, and intraoperatively, traction was continued. The segments were still in nonreduced position [Figure 2a]. Cervical and dorsal spinous processes from C1 to T1 were exposed through a midline incision. Lamina and lateral masses were exposed from C3 to C7 levels, and screw entry points were identified. Lateral mass screws were placed from C3 to C7 levels bilaterally under radiographic guidance [Figure 2b]. Laminae were fractured and moving freely and to avoid inward impingement of the broken fragments and provide space for edematous cord to expand laminectomy was performed. Titanium rods were placed in screw heads, and nuts were tightened in



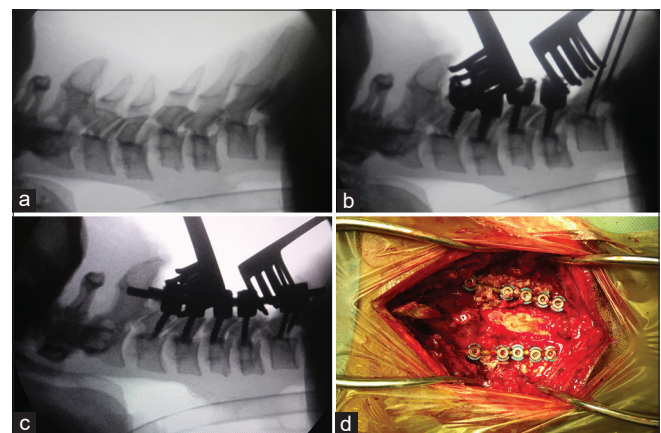
**Figure 1:** Sagittal T1 (a) and T2 (b) of the cervical spine showing multilevel anterior subluxations at C4 over C5 and C6 over C7 vertebrae with lax anterior and posterior longitudinal ligaments, severe cervical cord compression noted at C4–5 level and cord edema from C3–C7 levels. Sagittal computed tomography reformed images (c and d) show locked facet joints at C4–5 and C6–7 levels

sequential manner (to achieve Zip effect) which resulted in good reduced position of the subluxated vertebral bodies [Figure 2c and d]. Bone chips obtained from laminectomy were used to achieve fusion. The patient was kept on elective ventilation and could be gradually weaned off. The patient was stable at 6-month follow-up; however, there was no improvement in his neurological status.

## Discussion

The reported incidence of spinal injuries involving the cervical region is up to 3%, and up to 6.7% of the patients can have dislocation of the facets joints (usually C5–C6 and C6–C7 levels).<sup>[6]</sup> Involvement of the multiple spinal regions is reported in as many as 4.8% of patients with spinal injuries;<sup>[7]</sup> however, cervical dislocation involving two levels is uncommon with only two reported cases of adjacent levels of dislocation.<sup>[8,9]</sup> Usually, these uncommon injuries are caused by fall from high heights (in presented case tree),<sup>[5]</sup> the abnormal axial loading, flexion, and rotation can lead forces that cause compression, shear, and rotation forces at multiple levels.<sup>[8,9]</sup>

Surgical management of these unstable cases is not only controversial but also is a challenge for the treating personnel.<sup>[10]</sup> Initial traction can help to reduce the dislocation in selected cases; however, if this not reduce the dislocation neurosurgical intervention (i.e., anterior or posterior or a combined approach) to achieve open reduction is suggested.<sup>[8,11]</sup> Of the two reported cases of adjacent level dislocation involving cervical region, one case was managed by anterior only approach,<sup>[9]</sup> and the other case was managed through posterior only approach.<sup>[8]</sup> In the reported cases, the authors approached from posteriorly (one level above and one level below) and could achieve good reduction and



**Figure 2:** (a) Intraoperative radiographic image showing C4 and C6–7 subluxation, (b) placement of lateral mass screws, (c) good alignment of vertebrae after tightening the screws, and (d) intraoperative image showing the position of the screw heads

stability using wire and iliac crest graft.<sup>[9]</sup> It can be argued that posterior approach alone may not provide anterior support; hence, anterior approach may also be needed to achieve stability.<sup>[8,12,13]</sup> However, with the advancements in surgical techniques, the posterior approach can provide adequate reduction under direct vision and stable fixation with lateral mass screws and rods.<sup>[14]</sup>

## Conclusion

It has been reported that spinal injuries involving multiple-level noncontiguous level have an increased risk of deformity<sup>[9]</sup> and have poorer neurological outcome.<sup>[15]</sup> Posterior only approach can be used in unstable patients who sustain nonadjacent levels traumatic dislocation of the cervical spine.

## Declaration of patient consent

The authors certify that they have obtained all appropriate patient consent forms. In the form the patient(s) has/have given his/her/their consent for his/her/their images and other clinical information to be reported in the journal. The patients understand that their names and initials will not be published and due efforts will be made to conceal their identity, but anonymity cannot be guaranteed.

## Financial support and sponsorship

Nil.

## Conflicts of interest

There are no conflicts of interest.

## References

1. Kewalramani LS, Taylor RG. Multiple non-contiguous injuries to the spine. *Acta Orthop Scand* 1976;47:52-8.
2. Bentley G, McSweeney T. Multiple spinal injuries. *Br J Surg* 1968;55:565-70.
3. Griffith HB, Gleave JR, Taylor RG. Changing patterns of fracture in the dorsal and lumbar spine. *Br Med J* 1966;1:891-4.
4. Roberts JB, Curtiss PH Jr. Stability of the thoracic and lumbar spine in traumatic paraplegia following fracture or fracture-dislocation. *J Bone Joint Surg Am* 1970;52:1115-30.
5. Wang CM, Chen Y, DeVivo MJ, Huang CT. Epidemiology of extraspinal fractures associated with acute spinal cord injury. *Spinal Cord* 2001;39:589-94.
6. Payer M, Tessitore E. Delayed surgical management of a traumatic bilateral cervical facet dislocation by an anterior-posterior-anterior approach. *J Clin Neurosci* 2007;14:782-6.
7. Vital JM, Gille O, Sénégas J, Pointillart V. Reduction technique for uni- and biarticular dislocations of the lower cervical spine. *Spine (Phila Pa 1976)* 1998;23:949-54.
8. Bourghli A, Vital JM, Boissière L, Obeid I. Two adjacent levels dislocation of the cervical spine managed via an anterior only approach. A case report. *J Med Liban* 2016;64:181-5.
9. Eismont FJ, Borja F, Bohlman HH. Complete dislocations at two adjacent levels of the cervical spine. A case report. *Spine (Phila Pa 1976)* 1984;9:319-22.
10. Lee JY, Nassr A, Eck JC, Vaccaro AR. Controversies in the treatment of cervical spine dislocations. *Spine J* 2009;9:418-23.
11. Wang B, Zhu Y, Jiao Y, Wang F, Liu X, Zhu H, *et al.* A new anterior-posterior surgical approach for the treatment of cervical facet dislocations. *J Spinal Disord Tech* 2014;27:E104-9.
12. Razack N, Green BA, Levi AD. The management of traumatic cervical bilateral facet fracture-dislocations with unicortical anterior plates. *J Spinal Disord* 2000;13:374-81.
13. Reindl R, Ouellet J, Harvey EJ, Berry G, Arlet V. Anterior reduction for cervical spine dislocation. *Spine (Phila Pa 1976)* 2006;31:648-52.
14. Korres D, Nikolaou VS, Kaseta M, Evangelopoulos D, Markatos K, Lazaretos J, *et al.* Posterior stabilization of cervical spine injuries using the roy-camille plates: A long-term follow-up. *Eur J Orthop Surg Traumatol* 2014;24 Suppl 1:S125-30.
15. Gupta A, el Masri WS. Multilevel spinal injuries. Incidence, distribution and neurological patterns. *J Bone Joint Surg Br* 1989;71:692-5.