

Surgical management of congenital idiopathic clubfoot by twin incisions

H. S. Varma, Alok C. Agrawal¹, Pradeep K Singh²

Netaji Subhash Chandra Bose Medical College, Jabalpur, Madhya Pradesh, India, ¹AIIMS, Raipur, Chhattisgarh, ²Department of Orthopaedics and Trauma, JN Medical College, Wardha, Maharashtra, India

Address for correspondence:

Dr. Pradeep Singh,
Department of Orthopaedics and Trauma, JNMC, DMIMS, Wardha - 442 004, India.
E-mail: drpradeepsingh@gmail.com

ABSTRACT

Background: Idiopathic clubfoot surgery is known for a number of complications, that is, skin slough and wound dehiscence medially, infection and limitation of full correction at the time of surgery which leads to excessive scar hypertrophy, recurrence of deformity, and a poor functional outcome. Many procedures done in the past have reported complications ranging from 3 to 30%. We are doing surgical correction of congenital idiopathic clubfoot by two incisions avoiding dissection of the medial skin to overcome these problems and are reporting our results. **Materials and Methods:** We used two incisions (a medial and a posterior incision) in cases with moderate to severe congenital idiopathic clubfoot. These were those cases who did not want to continue with Ponseti's technique so as to avoid repeated follow-ups. Assessment of results was done by comparing preoperative and postoperative Pirani scores. **Results:** Our results were excellent in 7.9% (6 feet), good in 72.3% (55 feet), and fair in 15.8% (12 feet) cases. All of our cases had primary wound healing and no delayed scar related complication. **Conclusions:** Two incisions avoid stress on the medial skin. They permit release of all contracted structures posteromedially. We are describing this technique for its simplicity.

Keywords: Congenital, idiopathic clubfoot, simple, two incisions

Introduction

Surgery for congenital idiopathic clubfoot has a number of complications in the postoperative period such as delayed wound healing, gaping, infection, and recurrence of the deformity. Multiple types of surgical approaches have been described in literature with the aim to reduce the complications and give adequate tissue exposure so as to release all contractures and allow the incision to heal primarily without wound dehiscence or scar contracture.

Access this article online

Quick response code



Website:
www.joas.in

DOI:
10.4103/2319-2585.117383

The two most commonly used incisions: Turco and Cincinnati have been reported to have wound complications like skin slough, dehiscence, infection, and limitation of full correction at the time of surgery in 3-30% of cases leading to hypertrophic scar and recurrence of the deformity.^[1-4]

In India, a subtropical country, healing gets markedly delayed if the surgical wound gets infection or there is wound dehiscence. Maintaining the foot in correction in a plaster of Paris cast along with a window for dressing in a hot and humid climate, makes the task more difficult due to soiling of the cast leading to breaking and further infection. With Ponseti's technique coming in vogue surgeries have become less and even if surgery is required, it need not be as extensive as with the Cincinnati^[5] complete subtalar release or Turco's^[6] posteromedial release. We have used twin incisions, a modification of NC Carroll's technique making it simpler for the correction of the idiopathic clubfoot to avoid the above mentioned complications. In this technique two incisions are given, sparing the midincision zone of Turco's incision, reducing the chances of gaping or infection. Dual incisions have been also described by Carroll.^[1,2] They differ from our incisions as the medial incision on the foot in the Carroll's technique is used to raise a flap for complete subtalar release which at times may undergo marginal flap necrosis.

We find the procedure simple and easy to learn and recommend it for clubfoot surgery.

Materials and Methods

Seventy-six idiopathic clubfoot in 56 children aged 3-18 months (average 9 months), presenting to us from January 1997 to June 2007, were treated by us by a medial and a posterior incision, sparing the intervening skin and dissection for posteromedial release following percutaneous plantar fasciotomy. Forty-two of these children were male and 14 were female. There was bilateral involvement in 20 children. All these feet had moderate to severe deformity as assessed by Pirani score. A foot with a Pirani score as modified by Flynn *et al.*,^[7] less than 2.5 and which got corrected with Ponseti's weekly casting was considered as mild. A foot was considered to be having moderate deformity when the child had a Pirani score between 2.5 and 5 (21 feet). These feet did not get corrected fully with weekly Ponseti's casting or recurred in a few weeks' time due to poor parent compliance, ignorance, illiteracy, or low socioeconomic status.^[3] A foot was said to be having severe deformity if the Pirani score was more than 5 (55 feet). Very rigid feet, with a Pirani score above 6, neglected CTEV with bony deformity and candidates with secondary clubfoot were not considered to be fit for this procedure. The surgery was done with patient in semisupine position and a sandbag put below the opposite iliac crest and lateral border of the operative foot touching the couch.

The twin incisions used were:

- A medial incision
- A posterior incision.

The technique is described below:

Medial incision

The incision is started 1 cm behind and above the medial malleolus along its posterior border and is curved down to middle of the first metatarsal. After identifying upper border of abductor hallucis muscle (AH), it is retracted down. The dissection is done straight down to the deep fascia, so as to avoid superficial dissection and jeopardize the vascularity of flaps raised. Behind the medial malleolus, the sheath of tibialis posterior (TP) and adjoining flexor digitorum longus (FDL) tendon is identified. This is made easy by the fact that the TP tendon is three times thicker than the FDL tendon. The superficial part of deltoid ligament and the spring ligament are cut. The TP tendon is cut and followed down to the navicular tuberosity and all its insertions are excised. The proximal cut end of TP is sutured to the tendon of FDL, and can be used in future as a motor unit for tendon transfer. Capsulotomy of talonavicular, naviculocuneiform, and cuneiform-first metatarsal joints is done. If necessary, Z-plasty of FDL and flexor hallucis longus (FHL) tendons is done to avoid clawed toes. The anteromedial subtalar joint between navicular and sustentaculum tali is opened. The tendon of AH is cut and reduction of navicular confirmed.

Posterior incision

The incision is made approximately 3" vertically along the lateral border of tendo Achilles. Z-plasty is done with medial division in the distal segment. The distal segment is reflected and space

between FHL and peroneus longus (PL) is developed. By forcefully dorsiflexing the foot, posterior capsule of the ankle and subtalar joints was stretched and the posterior capsule of the ankle joint, subtalar joint, and interosseus talocalcaneal ligament all were cut from here. Posterior talofibular and calcaneofibular ligaments are cut. Z-plasty of tendo Achilles is done with foot in neutral position. Closure is done in two layers. Deep layer is repaired by 3.0 vicryl and skin by 3.0 prolene, ethilon, or silk [Figures 1 and 2]. A well-padded cast above the knee without stress on suture line is applied for 3 weeks [Figure 3] followed by removal of sutures and keeping foot in maximum possible abduction and dorsiflexion without pain for a further duration of 3 weeks in the AK cast. Further maintenance of correction is achieved by keeping the foot in surgical shoes maintaining 150 dorsiflexion of ankle and eversion of foot for further 6 weeks duration. The children were advised stretching, consisting of manipulation of the foot by mother to full or slight overcorrection of equinus, and eversion for 5 min at least three times a day for the next 3-6 months. Figures 4-5 shows the postoperative appearance and 6 year follow-up of the same child. Final results were assessed at two years by an improvement in the Pirani score to less than 0.5 as good, less than 1.5 as fair, and less than 2.5 as poor.

Results

Average age at surgery was 13 months (9-20 months). Follow-up evaluation was done at 2 years. The maximum long follow-up is of 7 years. The average surgical time was 45 min. The average wound healing time was 14 days ranging from 10 to 30 days. On comparison of the preoperative and postoperative Pirani score with number of patients, it was found that six patients improved to 0-0.5, 55 improved to 0.5-1.5, 12 improved to 1.5-2.5. 3 patients still had a Pirani score above 2.5 and were categorized as poor results. Number of patients with a preoperative Pirani score of 5-6 was 55 which came to 0 postoperatively [Table 1]. Only 3 feet (3.9%) had a residual forefoot adduction at 1-year.

We used the Chi-square test to assess our results as follows:

Preoperative group:

χ^2 trend = 128.719

$P < 0.000001$

Postoperative group:

$\chi^2 = 141.50$ at 4 degrees of freedom

$P < 0.000001$

Upon comparison of Pirani score between preoperative and postoperative groups, we observed a positive linear trend and significant reduction of the cases towards the poorer scores. The finding was statistically significant; χ^2 trend = 128.719, $P < 0.000001$ and $\chi^2 = 141.50$; $P < 0.000001$; respectively. This suggests that the technique of simple twin incisions significantly increases the probability of better results ($P < 0.000001$). We had excellent results in six (as seen by postoperative Pirani score below 0.5), good in 55 (as seen by postoperative Pirani score < 1.5) [Figures 5] and fair results in 12 feet (as seen by postoperative Pirani score below 2.5). A foot resisting treatment, not acceptable socially was taken as a failure of treatment as seen in 3 feet with

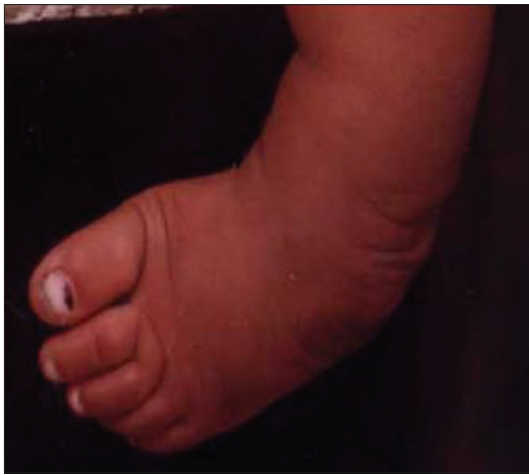

Figure 1: Preop photograph of the Left foot

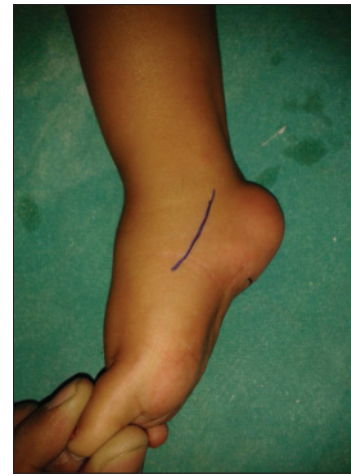

Figure 2: Pre operative planning of incision

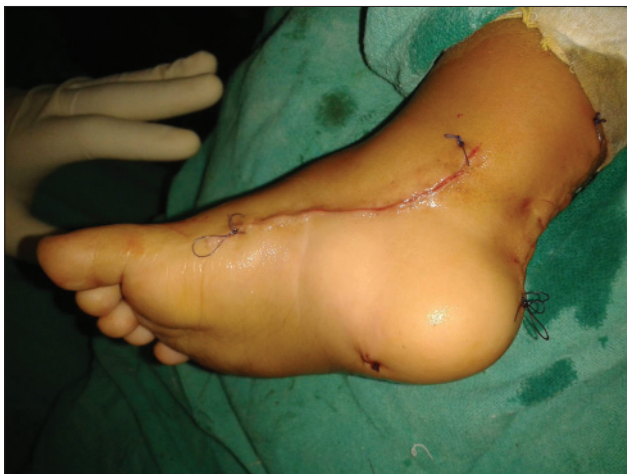

Figure 3: Postop photograph showing both medial and posterior incisions. Good approximation with easy closure

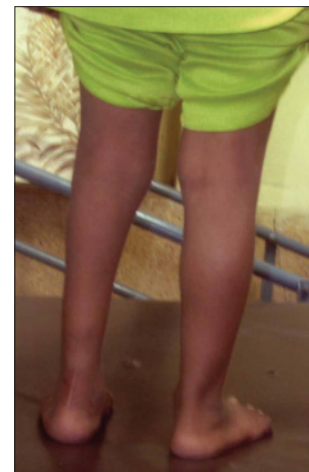


Figure 4: Postoperative photo showing good correction and cosmetic scar

a follow-up Pirani score above 2.5. These feet were reoperated at 1 year with cuboid decancellation and have good results now. None of the cases had postoperative wound gaping or infection.

Discussion

Postoperative wound complications are significant in India due to its subtropical location with hot and humid climate leading to increased chances of skin and soft tissue infection resulting in recurrence of the deformity.

Characteristics of these complications can be associated with the surgical approach used.^[8] Wound complications following posteromedial release are inherent to the technique only as the contracted skin posteromedially will never suffice as a cover once the foot is brought to the neutral position. Turco's technique^[6] advocates casting in under correction followed by gradual correction in serial casting in weekly casts. This is a difficult situation as the parents expect the child to have normal foot once surgery is over and repeated casting at times under anesthesia

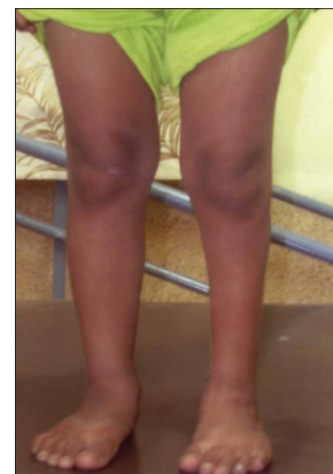

Figure 5: Normal plantigrade foot with excellent functional result

increases the financial cost as well as agony to the patient. At times patients prefer to accept deformity rather than come repeatedly for follow-ups due to poverty and illiteracy. A wound

Table 1: Assessment of foot correction by preoperative and postoperative Pirani scores

| Pirani score | Preop cases | Postop cases |
|--------------|-------------|--------------|
| 0-0.5 | 0 | 6 |
| 0.5-1.5 | 0 | 55 |
| 1.5-2.5 | 0 | 12 |
| 2.5-5.0 | 21 | 3 |
| 5.0-6.0 | 55 | 0 |
| Total | 76 | 76 |

with infection, gaping, and persistence of deformity is taken as a sign of failed surgery.

Two incisions for complete subtalar release have also been described by Carroll NC^[1,2] where he uses a posterior incision similar to our incision and a medial, distally based flap. This flap is reported to get necrosed. Our incisions are different. Our medial incision follows the distal part of Mackay^[9] incision and our posterior incision is lateral to the tendo Achilles. Our incisions for posteromedial release overcome these problems of wound healing as they neither put tension on the medial incision nor on the posterior incision. The medial skin where maximum tension is expected is not violated at all and even on stretching it does not give way. The intact bridge of skin between the two incisions never showed signs of vascular compromise or necrosis.

A reduction below 0.5-1 of Pirani score was achieved in 80.2% feet which is found to be acceptable in moderate to severe cases. In cases with residual forefoot adduction with rigid deformity or an initial severe deformity, cuboid decancellation is done. This may be done at the time of first surgery only or at a later date for forefoot adduction. Thus, it has the advantage to maintain a normal looking foot with preserved joint functions. In our series we did cuboid decancellation in 3 feet only at repeat surgery of poor results.

We compared our results with those of other published studies and we have found a bilateral versus unilateral ratio of 51.56:49.44 comparable to that of Turco *et al.*,^[10] 55:45. Skin necrosis rate as described by Turco in 1971^[10] was 6%, and Aggarwal *et al.*,^[11] was 3%. However, we found no skin necrosis following our technique of two incisions. We had a recurrence rate of 3.9%, maybe due to starting the treatment late in some patients and failure to carry out postoperative regimen of gentle stretching. However, surgically treated clubfeet, in which at least part of the

retracted ligaments are removed and the tendons are lengthened, frequently relapse as well, presumably due to surgical scar and muscle fibrosis.^[12] The overall results as reported by Turco^[10] for his procedure on 31 cases in 1971 was 90% success and 10% failure. In our series, we had 7.9% excellent, 72.3% good, 15.8% fair, and 3.9% poor results.

We recommend these two incisions in the operative correction of moderate to severe idiopathic clubfoot because we did not observe any wound related complications and achieved full correction of the foot.

References

1. Carroll NC, McMurtry R, Leete SF. The pathoanatomy of congenital clubfoot. *Orthop Clin North Am* 1978;9:225-32.
2. Carroll NC. Congenital clubfoot: Pathanatomy and treatment. *Instr Course Lect* 1987;36:117-21.
3. Crawford AH, Gupta AK. Clubfoot controversies: Complications and causes for failure. *Instr Course Lect* 1996;45:339-46.
4. Hutchins PM, Foster BK, Paterson DC, Cole EA. Long-term results of early surgical release in club feet. *J Bone Joint Surg Br* 1985;67:791-9.
5. Crawford AH, Marxen JL, Osterfeld DL. The Cincinnati incision: A comprehensive approach for surgical procedures of the foot and ankle in childhood. *J Bone Joint Surg Am* 1982;64:1355-8.
6. Turco VJ. Surgical correction of the resistant club foot. One-stage posteromedial release with internal fixation: A preliminary report. *J Bone Joint Surg Am* 1971;53:477-97.
7. Flynn JM, Donohoe M, Mackenzie WG. An independent assessment of two clubfoot-classification systems. *J Pediatr Orthop* 1998;18:323-7.
8. Singh BI, Vaishnavi AJ. Modified Turco procedure for treatment of idiopathic clubfoot. *Clin Orthop Relat Res* 2005;438:209-14.
9. McKay DW. New concept of and approach to clubfoot treatment: Section II--correction of clubfoot. *J Pediatr Orthop* 1983;3:10-21.
10. Turco VJ. Surgical correction of resistant clubfoot. One-stage posteromedial release with internal fixation: A preliminary report. *J Bone Joint Surg* 1971;53:477-97.
11. Aggarwal ND, Singh HS, Mittal RL. Evaluation of tibialis posterior transfer on surgical treatment of congenital clubfoot. *IJS* 1967;29:4-105.
12. Goldner, J.L. and Fitch, R.D. (1994). Classification and evaluation of congenital talipes equinovarus. In, *The clubfoot*, (ed. G.W. Simons). Springer-Verlag, New York.

How to cite this article: Varma HS, Agrawal AC, Singh PK. Surgical management of congenital idiopathic clubfoot by twin incisions. *J Orthop Allied Sci* 2013;1:18-21.

Source of Support: Nil, Conflict of Interest: None declared.