

Case Report

A rare case report of extraosseous osteosarcoma in a 35-year-old female

Divya Mahajan¹, Bhupender Bhupender¹, Umang Gauba¹, Kislay Dimri¹

¹Department of Radiation Oncology, Government Medical College and Hospital, Chandigarh, India.

*Corresponding author:

Divya Mahajan,
Department of Radiation
Oncology, Government
Medical College and Hospital,
Chandigarh, India.

Indidivmaha28@gmail.com

Received: 20 July 2023

Accepted: 24 July 2023

Epub Ahead of Print: 30 November 2024

Published:

DOI

10.25259/Joasp_33_23

Quick Response Code:



ABSTRACT

Extraosseous osteosarcoma is a rare tumour that mostly affects males more than females. It accounts for 1.2% of all soft tissue sarcomas. It arises from soft tissues without direct attachment to the skeletal system and produces osteoid, bone, or chondroid material. Extraosseous osteosarcoma usually occurs middle-aged and elderly patients (5th–6th decade of life). Extraosseous osteosarcoma is highly aggressive. Due to rarity of this tumour, few data is available in the literature regarding the causes, symptom, and treatment of the disease hence this case report aims to focus some light on the rarity of this tumour along with its radiological features, presentations, and course of treatment. Here, we are discussing a rare case of extraosseous osteosarcoma of 35-year-old female with no prior history of trauma or radiation exposure.

Keywords: Extraosseous osteosarcoma, Extraskelatal osteosarcoma, Soft tissue sarcoma.

INTRODUCTION

Extraosseous osteosarcoma is a rare form of soft tissue tumour. It arises from soft tissues without direct attachment to the skeletal system and produces osteoid, bone, or chondroid material. It is a malignant mesenchymal neoplasm with less than 300 cases reported to date.¹ Extraosseous osteosarcomas account for 1.2% of all soft tissue sarcomas.² Osteosarcomas of bone usually affect young adults and adolescents, whereas extraosseous osteosarcomas usually occurs in middle-aged and elderly patients (5th–6th decades of life).³ Extraosseous osteosarcoma is diagnosed histologically by the presence of neoplastic osteoid and bone, sometimes with neoplastic cartilage. Various histological variants of extraosseous osteosarcoma are osteoblastic, chondroblastic, fibroblastic, osteoclastic, small cell, telangiectatic, and lately, giant cell malignant fibrous histiocytoma-like pattern added in 1990.⁴

Due to the rarity of this tumour, little data is available in the literature regarding the causes, symptoms, and treatment of the disease. Therefore, this case report aims to shed some light on the rarity of this tumour as well as its radiological features, presentations, and course of treatment.

CASE REPORT

Here, we present the case of a 35-year-old female who presented to the outpatient department with a chief complaint of swelling over the posterior aspect of the right knee. The swelling was associated with pain on flexion of the knee and subsided upon extension. The swelling was initially small in size but increased over time. The swelling was not associated with any history

This is an open-access article distributed under the terms of the Creative Commons Attribution-Non Commercial-Share Alike 4.0 License, which allows others to remix, transform, and build upon the work non-commercially, as long as the author is credited and the new creations are licensed under the identical terms.

©2024 Published by Scientific Scholar on behalf of Journal of Orthopaedics and Spine.

of deformity, trauma, fractures, or a history of radiation. The swelling was soft and fluctuant. The slip sign was negative and appeared to be adherent to underlying tissue. The overlying skin is free. Contrast enhanced magnetic resonance imaging (CE-MRI) was done which indicated $4 \times 4.2 \times 9.6$ cm (Anteroposterior \times Transverse \times Craniocaudal) involving the inter/intramuscular plane of the medial compartment of the distal 1/3rd part of the right thigh with involvement of the gracilis muscle and tendon and causing muscle expansion resulting in mass effect on the semimembranosus muscle and superficial femoral vessel pushing this structure medially, with normal intervening fatty planes [Figure 1]. The biopsy suggested osteosarcoma [Figure 2]. The patient was administered three cycles of adriamycin and cisplatin. CE MRI indicated a $9.5 \times 4.5 \times 3.5$ cm mass arising from the gracilis muscle and resulted in significant expansion with extension into adjacent intermuscular planes, consistent with soft tissue sarcoma [Figure 3]. Then, a tumour resection of the

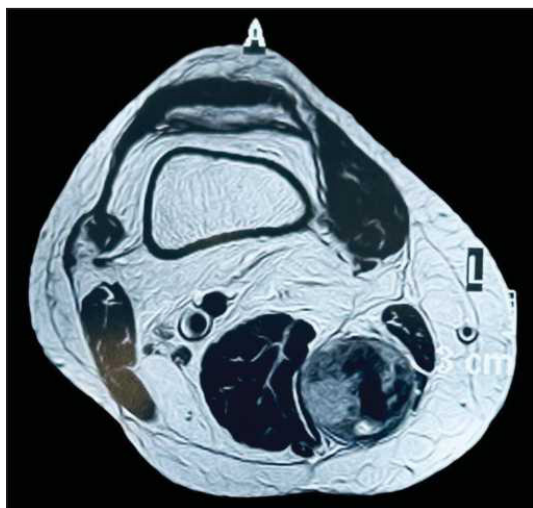

Figure 1: Axial section in CE MRI reveals a heterogeneous mass of size $4 \times 4.2 \times 9.6$ cm in muscle without any continuity to bone.

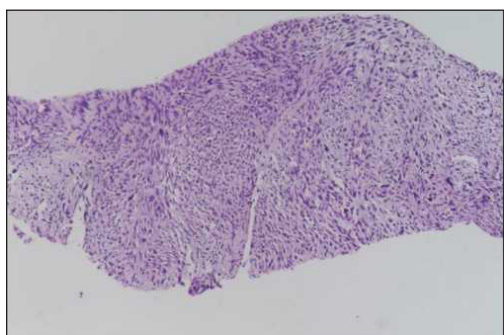


Figure 2: 20 \times hist section of tumour showing malignant cells with anisonucleosis and pleomorphism. (Hematoxylin and eosin stain)

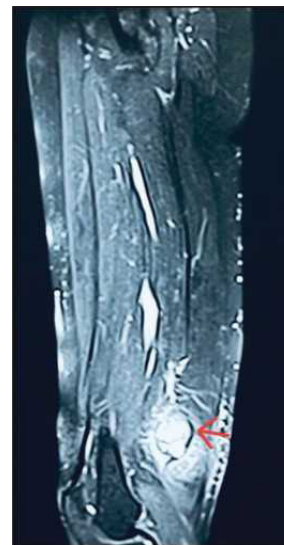

Figure 3: CE MRI of right thigh showing a soft tissue mass of $9.5 \times 4.5 \times 3.5$ cm (red arrow).

right thigh was performed. The size of the resected specimen is $13 \times 5.5 \times 4$ cm and the tumour is grey-white to grey-brown and measures $6.5 \times 3.6 \times 3.5$ cm. Tumour cells are large oval to spindle-shaped with coarse to vesicular nuclear chromatin. Pleomorphic-type tumour cells can be seen. A large area of necrosis was visible. Adjacent muscle and both resection limits are free of tumour. Then, the patient received two more cycles of chemotherapy. The patient is currently under treatment and is showing significant improvement in symptoms.

DISCUSSION

Risk factors for extraosseous osteosarcoma include a history of prior radiation exposure,⁵ previous trauma, intramuscular injection,⁶ myositis ossificans,² heterotrophic ossification of dermatomyositis,⁷ and a previous bone graft.⁸ Genetic conditions such as Paget's disease, fibrous dysplasia, Li Fraumeni, Thompson-Nicola, and retinoblastoma syndromes and following radiation therapy.⁹ Extraosseous osteosarcoma usually occurs in men in the sixth decade of life. The most common site of occurrence is the lower extremity, especially the thigh, followed by the upper limb and retro peritoneum, respectively, the thyroid gland, penis, mediastinum, and kidney have also been reported.¹⁰ Extraosseous osteosarcoma on radiography appears as soft tissue mass with variable degrees of calcification.¹¹ Spotty calcification or dense cloud-like opacity. CE MRI is used to identify tumour extent and to exclude the continuity of the tumour with the cortex and bone marrow. Tumour in continuity with the bone is associated with bone origin rather than soft tissue.

Due to the rarity of the tumour, there is no standard treatment for extraosseous osteosarcomas. In 1971, Allan and Soule treated 26 cases of Ewing's sarcoma of the bone by amputation, and the results showed an improvement in survival and a decrease in the local recurrence rates.¹² Ahmed and Patel¹ found that patients with extremity Ewing's sarcoma of the bone who underwent limb salvage procedures using clinical and anatomical criteria had a five-year local recurrence-free survival rate of 82%. A wide local excision with a 5-cm margin is recommended as the treatment of choice.¹⁰ However, if the tumour is located in an anatomically challenging area where a wide margin cannot be achieved, amputation is recommended. Patients with localised Ewing's sarcoma who receive a chemotherapy regimen such as doxorubicin, sulfonamide, cisplatin, and possibly methotrexate, similar to that used for osteosarcoma after surgery, have shown promising outcomes with a five-year survival rate ranging from 66 to 77%.¹³ This is much higher than the survival rate for patients who undergo surgery alone, which ranges from less than 25 to 50%. Tumour size is the most reliable predictor of outcome, with smaller tumours at presentation (<5 cm) associated with a better chance of survival at 30 months. Radiation therapy is another effective treatment modality that can be combined with surgery to increase survival rates and delay recurrence. According to Sordillo's series, the median time to the first recurrence was significantly longer in patients who received radiation therapy after surgery compared to those who did not receive radiation therapy.³

Extraosseous osteosarcomas are tumours that have no or minimal association with the underlying skeleton or periosteum. It is important to distinguish these tumours from surface osseous osteosarcomas, such as parosteal, periosteal, and high-grade surface osteosarcomas. Parosteal osteosarcomas are the most common subtype of surface osteosarcomas, accounting for 65% of cases. They are usually well-differentiated tumours that wrap around the bone and can be mistaken for osteochondromas based on their clinical presentation. Typically, these tumours are found in the metaphysis of long bones, especially the distal femur, and appear as a lobulated "cauliflower-like" mass adjacent to the bone. Periosteal osteosarcomas account for 25% of surface osteosarcomas and often arise in the diaphysis or metadiaphysis of long bones. They have a perpendicular periosteal reaction that extends into a soft tissue mass and often have a chondroblastic appearance. High-grade surface osteosarcomas make up about 10% of surface osteosarcomas and have a histological appearance similar to high-grade osteoblastic osteosarcomas.¹⁴ Tumour size (<5 cm vs >5 cm), age at presentation, and tumour volume are major factors predicting patient survival.³

CONCLUSION

Extraosseous osteosarcoma is resistant to doxorubicin, a chemotherapy drug, and has a bleak prognosis. The author also suggests that extraosseous osteosarcoma should be considered as a separate entity from osseous osteosarcoma. It is further stated that optimal treatment for extraosseous osteosarcoma is uncertain, and recommended that after a definitive surgery (which may involve either wide excision or amputation), further treatment options such as adjuvant chemotherapy and radiation should be considered.

Ethical approval

Institutional Review Board approval is not required.

Declaration of patient consent

Patient's consent not required as patients identity is not disclosed or compromised.

Financial support and sponsorship

Nil.

Conflicts of interest

There are no conflicts of interest.

Use of artificial intelligence (AI)-assisted technology for manuscript preparation

The authors confirm that there was no use of artificial intelligence (AI)-assisted technology for assisting in the writing or editing of the manuscript and no images were manipulated using AI.

REFERENCES

1. Ahmad SA, Patel SR, Ballo MT, Baker TP, Yasko AW, Wang X, et al. Extraosseous osteosarcoma: Response to treatment and long-term outcome. *J Clin Oncol* 2002;20:521–7.
2. Chung EB, Enzinger FM. Extraskelatal osteosarcoma. *Cancer* 1987;60:1132–42.
3. Sordillo PP, Hajdu SI, Magill GB, Golbey RB. Extraosseous osteogenic sarcoma: A review of 48 patients. *Cancer* 1983;51:727–34.
4. Bane BL, Evans HL, Ro JY, Carrasco CH, Grignon DJ, Benjamin RS, et al. Extraskelatal osteosarcoma. A clinicopathologic review of 26 cases. *Cancer* 1990;65:2762–70.
5. Laskin WB, Silverman TA, Enzinger FM. Postradiation soft tissue sarcomas: An analysis of 53 cases. *Cancer* 1988;62:2330–40.
6. Lee JH, Griffiths WJ, Bottomley RH. Extraosseous osteogenic sarcoma following an intramuscular injection. *Cancer* 1977;40:3097–101.

7. Eckardt JJ, Ivins JC, Perry HO, Unni KK. Osteosarcoma arising in heterotopic ossification of dermatomyositis: Case report and review of the literature. *Cancer* 1981;48:1256–61.
8. Park SG, Song JY, Song IG, Kim MS, Shin BS. Cutaneous Extraskeletal Osteosarcoma on the scar of a previous bone graft. *Ann Dermatol* 2011;23:S160–4.
9. Rosenberg A. Extraskeletal osteosarcoma. Pathology and genetics of tumours of soft tissue and bone. Lyon: IARC Press 2002.
10. Dudhat S, Desai S, Borges A, Shinde S. Retroperitoneal extraosseous osteosarcoma. A case report and review of literature. *Indian J Cancer* 1999;36:186–9.
11. Kransdorf MJ, Meis JM. From the archives of the AFIP. Extraskeletal osseous and cartilaginous tumors of the extremities. *Radiographics* 1993;13:853–84.
12. Allan CJ, Solle EH. Osteogenic sarcoma of the somatic soft tissues. Clinicopathologic study of 26 cases and review of literature. *Cancer* 1971;27:1121–33.
13. Goldstein-Jackson SY, Gosheger G, Delling G, Berdel WE, Exner GU, Jundt G, et al. Extraskeletal osteosarcoma has a favourable prognosis when treated like conventional osteosarcoma. *J Cancer Res Clin Oncol* 2005;131:520–6.
14. Hoch M, Ali S, Agrawal S, Wang C, Khurana JS. Extraskeletal osteosarcoma: A case report and review of the literature. *Radiol Case* 2013;7:15–23.

How to cite this article: Mahajan D, Bhupender B, Gauba U, Dimri K. A rare case report of extraosseous osteosarcoma in a 35-year-old female. *J Orthop Spine*, doi:10.25259/Joasp_33_23.