

# Wakeboard accident, avulsion adductor longus

Sir,

I would like to share this rare case of a complete avulsion of adductor longus and sartorius muscle at the same time occurring on a wakeboarder.

Complete avulsion of the adductor longus muscle is uncommon in general, but it has been described in soccer, football, hockey, one case of skiing and horse riding.<sup>[1,2]</sup> The rider reported herein is an experienced wakeboarder, performing the sport since 25 years. He started from the regular position, left foot in front and legs deeply bended. Immediately after acceleration of the boat by the driver, he experienced popping and extreme pain in the left groin and suprapubic area.

Critical conditions at the wakeboard start are weight and training state of the rider (in this case, 169 cm and 69 kg, well trained) tension of the rope at the start, position and bending of legs on board. We can only speculate about the cause of the accident, but retrospectively an unusual acceleration speed of the boat with abrupt load on the rope and rider may have added possibly to the accident.

## Clinical

The clinical course was similar to most other cases but nearly identical in all aspects to the case reported by Lands *et al.*<sup>[2]</sup> The rider was brought on land, he presented with heavy pain as described. A medical investigation including palpation of inner thigh, groin, and suprapubic area was painful due to tissue damage and accompanying swelling. Passive abduction and adduction at this time were merely impossible, but the rider could walk with pain a few meter. For 2 days he rested.

## Diagnostic

On day 4 after the injury an ultrasonography [Figure 1] was performed and on day 5 a magnetic resonance imaging, [Figure 2a and b].

Both imaging modalities showed a complete avulsion of the adductor longus and sartorius muscle with retraction of the adductor longus tendon and muscle of about 8 mm from the pubic bone. Hematoma had developed rapidly and progressed over 5 days down to popliteal fossa.

## Therapy

The rider, after informed consent with experts, decided to apply conservative treatment, mainly because he learned that rehabilitation was a favorable option.

Since part of the pain was considered as consequence of inflammation a systemic treatment with prednisone was initiated (40 mg over 5 days, 20 mg over 5 days, and 10 mg for another 5 days). A general reduction of pain was noted 2 days after starting prednisone. The large cutaneous hematoma was treated with Hemoclar over 10 days. The swollen area left groin probably also due to the retracted muscle shrank satisfactorily, and most inner hematoma were resorbed after 12 days by inspection and palpation.

Rehabilitation exercises were started at day on day 5 after the accident consisting of physiotherapy following consultation with and personal advise by Thorborg *et al.*, University of Copenhagen<sup>[3]</sup> following the program published by Hölmich *et al.*<sup>[4]</sup> and intensified using TheraBand.

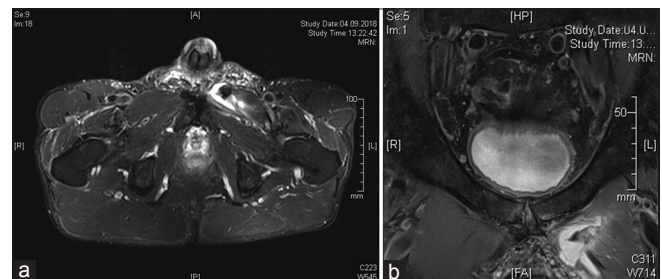
Only 2 days after initiation of this program general daily complaints vanished. On day 17, the rider was nearly free of pain during daily life and when performing the exercise program. Muscular exercises were intensified at day 18 using an adductor weight training machine (Techno Gym) starting with 20 kg.

Based on the mentioned literature a complete regeneration could be expected after 6–10 weeks with a return to board sports and this was the achieved also in this case.

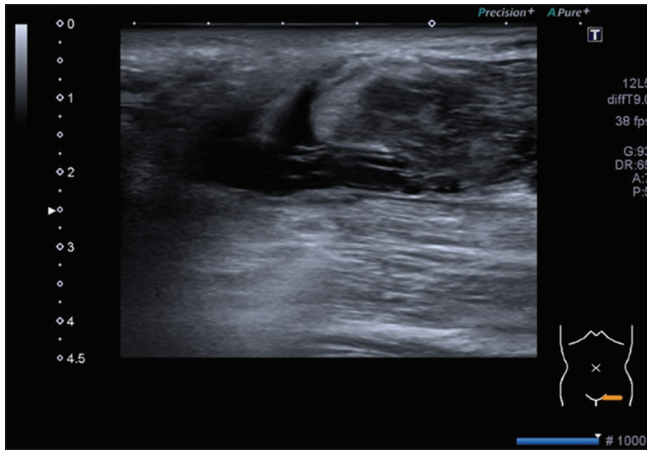
Thorborg, in his consulting, supposed that the avulsed muscle and his tendon may possibly find its way back.

## Conclusion

In summary, a conservative treatment of a completely avulsed adductor longus muscle as first here described on a wakeboarder, seems favorable over operative interventions, using an intense accelerated rehabilitation program. Early prednisone therapy, not reported so far, may be a valuable and effective intervention for pain



**Figure 1:** (a and b) Magnetic resonance imaging transverse showing complete osseous avulsion of adductor longus muscle, retraction 8 mm, hematoma



**Figure 2:** Ultrasonography: Complete avulsion of adductor longus muscle, retracted muscle, hematoma

and inflammation reduction with less risk than using nonsteroidal drugs which may intensify bleeding risk and hematoma forming.

**Acknowledgment**

The author would like to thank Dr. Denis Wetter, Radiology, Kantonsspital, CH-8596 Muensterlingen for performing ultrasound and magnetic resonance imaging studies.

**Financial support and sponsorship**

Nil.

**Conflicts of interest**

There are no conflicts of interest.

**Dieter Hesch<sup>1,2</sup>**

<sup>1</sup>Department Internal Medicine, Medical High School Hannover, Hannover, <sup>2</sup>Department of Surgery, Faculty of Biology, University of Konstanz, Konstanz, Germany


**Address for correspondence:**

Dr. Dieter Hesch,  
Mövenweg 87, Ch 8597 Landschlacht, Switzerland.  
E-mail: dieter@hesch.ch

**References**

1. van de Kimmenade RJ, van Bergen CJ, van Deurzen PJ, Verhagen RA. A rare case of adductor longus muscle rupture. *Case Rep Orthop* 2015;2015:840540.
2. Lands VW, Avery DM, Puccio ST. Complete avulsion of the adductor longus in a semi-professional football player: Rapid return to play with nonoperative treatment. *J Orthop Allied Sci* 2016;4:45-8.
3. Thorborg K, Petersen J, Nielsen MB, Hölmich P. Clinical recovery of two hip adductor longus ruptures: A case-report of a soccer player. *BMC Res Notes* 2013;6:205.
4. Hölmich P, Uhrskou P, Ulnits L, Kanstrup IL, Nielsen MB, Bjerg AM, *et al.* Effectiveness of active physical training as treatment for long-standing adductor-related groin pain in athletes: Randomised trial. *Lancet* 1999;353:439-43.

This is an open access journal, and articles are distributed under the terms of the Creative Commons Attribution-NonCommercial-ShareAlike 4.0 License, which allows others to remix, tweak, and build upon the work non-commercially, as long as appropriate credit is given and the new creations are licensed under the identical terms.

Access this article online	
<b>Quick Response Code:</b> 	<b>Website:</b> <a href="http://www.joas.in">www.joas.in</a>
	<b>DOI:</b> 10.4103/joas.joas_37_18

**How to cite this article:** Hesch D. Wakeboard accident, avulsion adductor longus. *J Orthop Allied Sci* 2018;6:97-8.

© 2018 Journal of Orthopaedics and Allied Sciences | Published by Wolters Kluwer – Medknow