

# A new technique for surgical management of old unreduced elbow dislocations: Results and analysis

Parag Garg, Soumya Paik, Sisir Sahoo, Vimal Raj, Aniruddha Pispati, Subhashish Mitra

Department of Orthopedics, Seth Sukhlal Karnani Memorial Hospital, Kolkata, West Bengal, India

## Address for correspondence:

Dr. Parag Garg,

Room No. 219, Doctors Quarters, Seth Sukhlal Karnani Memorial Hospital, AJC Bose Road, Kolkata - 700 020, West Bengal, India.

E-mail: [pgiluvu@gmail.com](mailto:pgiluvu@gmail.com)

## ABSTRACT

**Background:** Open reduction of neglected dislocations of elbow often leads to less than optimal results. Extensive release during reduction and early mobilization may lead to instability. Post-surgical immobilization to recover the stability leads to loss of range of motion. Arafiles described a technique of creating a cruciate ligament like structure to provide stability while early mobilization is advocated. We have modified this technique in several aspects. We report a retrospective analysis of 26 such cases where we evaluated and compared the standard immobilization technique of K-wires with this new modified technique.

**Materials and Methods:** Twenty-six consecutive cases of dislocated elbow with duration ranging from 4 to 56 months were included in this study. We performed standard open reduction and fixation with K-wire followed by immobilization for 3 weeks for the first 12 cases. In the next 14 cases after standard release and reduction we provided extra stability by adding a cruciate ligament like structure both on the medial and lateral side using autologous semitendinosus graft. Post-operative mobilization was advised the very next day. We evaluated the results of this technique and compared it with the previous one using MEPI scores, complication rate and radiological evaluation.

**Results:** The average follow-up duration for the 26 patients is 4.5 years (2–7 years). All patients achieved full functional ROM in both planes. The mean increase in the MEPI score was significantly more for group II (53.5) than group I (36.6). Movement, activities and stability was better for this group II. Complication rates for both were similar.

**Conclusion:** Providing stability at the time of operation with a mediolateral cruciate ligament provides the option of immediate mobilization post-operatively in open reduction of neglected dislocations of elbow. Thus, this technique provides excellent results disregarding the duration of dislocation with minimal morbidity for the patient.

**Keywords:** Cruciate ligament, old elbow dislocation, open reduction

Video available on:

[www.joas.in](http://www.joas.in)

## Access this article online

Quick response code



Website:  
[www.joas.in](http://www.joas.in)

DOI:  
10.4103/2319-2585.145599

## Introduction

Old unreduced elbow dislocations are not very uncommon in the Indian subcontinent<sup>[1-7]</sup> due to inaccessibility to healthcare and consequent inadequate treatment initially.<sup>[1-4]</sup> With the increasing duration of the persistent dislocation the chances of survival of the cartilage surface decreases.<sup>[1-8]</sup> Thus, arthroplasty/arthrodesis rather than an open reduction is favourable for such cases.<sup>[8-14]</sup> Arthrodesis of the elbow is a disabling option and is not very acceptable.<sup>[2,5,6]</sup> Arthroplasty on the other hand provides a better alternative but the cost of the implant is a major deterrent for the poor patients who could not afford even primary care for the dislocation. The inability to lift heavy weights is another contraindication for these patients who usually earn their living doing manual labour or agriculture.<sup>[11-14]</sup> Thus open reduction is the best option for such patients.<sup>[1-7]</sup> Stability is usually achieved by prolonged immobilization by inserting K-wire after open reduction, which prolongs the rehabilitation and is detrimental for the long-term results. The extra stability per operatively can be provided by using two cruciate-like ligaments for the ulnohumeral and radio-capitellar joints so that post-operatively early movement is permitted safely. We report a retrospective analysis of 26 neglected dislocation elbows where we evaluated and compared the

standard immobilization technique of K-wires with a modified technique of open reduction.

## Materials and Methods

This is a retrospective study of the 26 patients who presented with neglected dislocated elbow. Open reduction of the elbow joint and fixation with K-wires was done for the initial 12 patients (Group I). Later on we added an extra step of reinforcement by medial and lateral slings constructed with semitendinosus tendon graft so that we can avoid K-wire fixation (Group II,  $n = 14$ ). Delay in presentation of the cases varied from 4 to 56 months (mean 10.3 months). Eight patients had fractures around elbow either mal-united ( $n = 6$ ) or un-united ( $n = 2$ ). Three of them had more than 1 fracture along with the dislocation. These fractures included medial condyle fracture ( $n = 4$ ), lateral condyle fracture ( $n = 2$ ), olecranon fracture ( $n = 2$ ), radial head fracture ( $n = 2$ ) and coronoid fracture ( $n = 1$ ). The average age of the patients was 22.5 years (range 14 – 40 years) and most (20 out of 26) of them had dominant limb affection. There were 15 male and 11 female patients. None of them had distal neurological deficit. All of the patients were from poor socioeconomic condition. No surgical procedure had been performed on any of the patients for this condition though majority of them (23/26) had taken some form of local treatment in the form of, massage or splinting with sticks. The most consistent complaint was of loss of range of motion of elbow leading to impairment of daily activity with pain, swelling, clicking sound on elbow movement and cosmetic deformity [Table 1]. All patients were counselled about the treatment options, their expected results, advantages, disadvantages and complications. A special consent was taken from the last 14 patients for practicing the new technique and for harvesting semitendinosus graft.

### Operative procedure

The surgical technique for open reduction of the dislocated elbow was same for all 26 cases. We used a single midline posterior skin incision followed by a medial plus lateral approach in the deeper planes [Figure 1Aa]. First step was identification and preservation of ulnar nerve followed extensive release around the fibrosed joint but still trying to preserve the lateral and medial collateral ligaments or whatever was present left of them. This was achieved by working very close to the bone and not straying medially or laterally in the area of collaterals or whatever new fibrosed tissue was providing medio-lateral support. Radio-humeral horn was carefully identified and excised [Figure 1Ab]. This step facilitates radio-capitellar reduction. Special attention was taken to preserve all cartilage left on the joint surfaces. No peeling or nibbling of soft tissue around the articular cartilage was done as this might lead to peeling off of the articular cartilage layer. Instead, a sharp dissection with a knife was used to remove all the fibrosis around the joint. We did not use any V- Y plasty of triceps. Instead, we performed extensive release of the triceps sometimes even up to the upper-thirds of humerus, in which case a radial nerve exploration was mandatory. We found that with all

around release of the triceps, as well as capsular release around the joint, we were able to successfully reduce all 46 dislocated elbows [Figure 1Ac].

Reduction was followed by transhumeral fixation with 2–3, 2.5 mm K- wires in the first 16 cases. The K-wires were removed after 21–28 days after which gradual mobilization of the joint was done, passive followed by active, but no weight lifting was allowed. Movement was allowed initially in hinged elbow brace to provide medio lateral stability. The brace was discontinued after further 4 weeks and gradual weight lifting was allowed after this.

In the last 14 cases, we performed a modification of a technique originally published by Arafiles *et al.*<sup>[15]</sup> The technique involved construction of an anterior-posterior cruciate ligament like structure using the Palmaris longus tendon, so that early movement could be provided. Four holes are drilled, two each in the ulna and humerus to pass the tendon through them in a figure of eight fashion [Figure 1Ba]. The tendon comes out of the articular surface of the olecranon and enters the articular surface of trochlea, winds back on the lateral condyle and re-enters the ulna to be finally tied down on the posterior aspect of ulna [Figure 1Bb]. It is an intra-articular check rein mechanism, preventing subluxation of the joint while movement are allowed at the same time. We used the semitendinosus from the contralateral leg of the patient we found Palmaris longus too weak a structure for this operation. During the dissections, we also found lateral stability lacking even after this sling, especially in extension. So, we added an extra lateral sling using the same tendon. Here the tendon passes through the center of the radial head to the capitellum and is anchored on the lateral condyle

**Table 1: Demographics**

	<b>Group I - K wire fixation group N=12</b>	<b>Group II - Cruciate ligament reconstruction group N=14</b>
Average time lapse at presentation (months)	16 (4-48)	18.5 (6-56)
Associated fractures	4 (33%)	4 (29%)
Medial condyle	2	2
Lateral condyle	1	1
Olecranon	1	1
Radial head	1	1
Coronoid	1	0
Average age (years)	21 (14-36)	23.8 (16-40)
Dominant side	9	11
Male/female	7/5	8/6
Previous local management (bone setting, massage, splinting)	11	12
Complaint		
Loss of ROM	10	13
Loss of power/inability to do ADL		
Pain	8	12
Swelling	6	8
Cosmesis	6	8
Clicking sound	3	5

ROM = Range of motion, ADL = Activities of daily life

proximally and radial neck distally [Figure 1Bc and d]. Careful preservation of the posterior interosseus nerve is essential in this step. We omitted the step of creating a slot in the trochlea for passage of the tendon. More release of contracted tissues was done till we were able to achieve full ROM preoperatively. We checked for both antero-posterior and medio-lateral stability during various degrees of flexion and supination-pronation preoperatively, and adjusted our slings likewise [Video 1]. Satisfied with our construct and stability of elbow in all planes we allowed movement on the very next day of operation [Video 2]. The special attention was given to post-operative analgesia to allow pain free movement for

the patient. Active movement and gradual strengthening exercises were given over a period of 3 weeks. Light weight lifting was given after 4 weeks and full weight lifting after 3 months.

Follow-up was done at 4, 8, 12 weeks and then every 3 months. In our series the mean follow-up period for this series is 4.5 years, (range 2–7 years). Range of movement, pain, stability and ability to perform physical activity was assessed for MEPI score evaluation, while radiographic follow-up was done to assess for articular alignment. Post-traumatic arthrosis was graded using the Broberg and Morrey scale.<sup>[16]</sup>

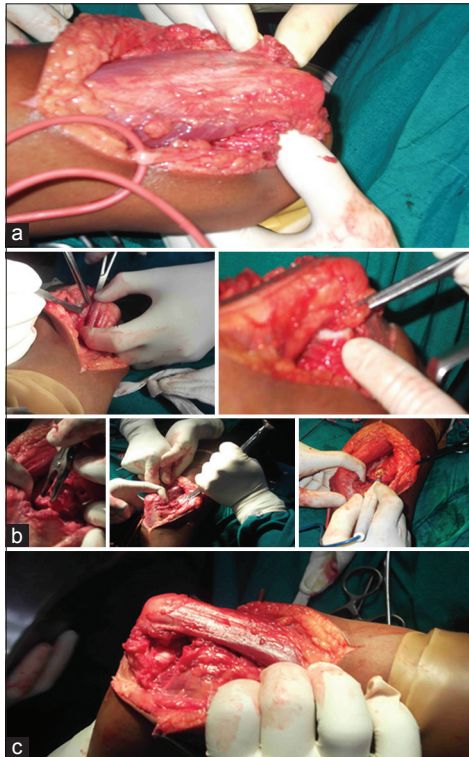
The patients were clinically evaluated for elbow movements, deformity and stability. The following parameters were recorded preoperatively and after 1 year of operation. (1) Range of motion (2) Mayo elbow performance index (MEPI). MEPI score measures the subjective, objective and functional parameters of the elbow in terms of pain, movement, stability and activities performed.<sup>[17]</sup> Radiological examination included anteroposterior and lateral views of injured elbows.

The mean range of flexion-extension before operation was 40° (Range 0°–70°), with even distribution between both the groups and the cases associated with fractures. Coronal plane instability was tested with elbow in 20° flexion. Side-to-side movement more than 5° was considered evidence of instability. Twenty-four of 26 patients had coronal plane instability, 20 having it on both sides, three on lateral side only while one had it on medial side only. The average instability was 12.5° with a range of 0–45°. The average MEPI score was 38.3 (range 24–58).

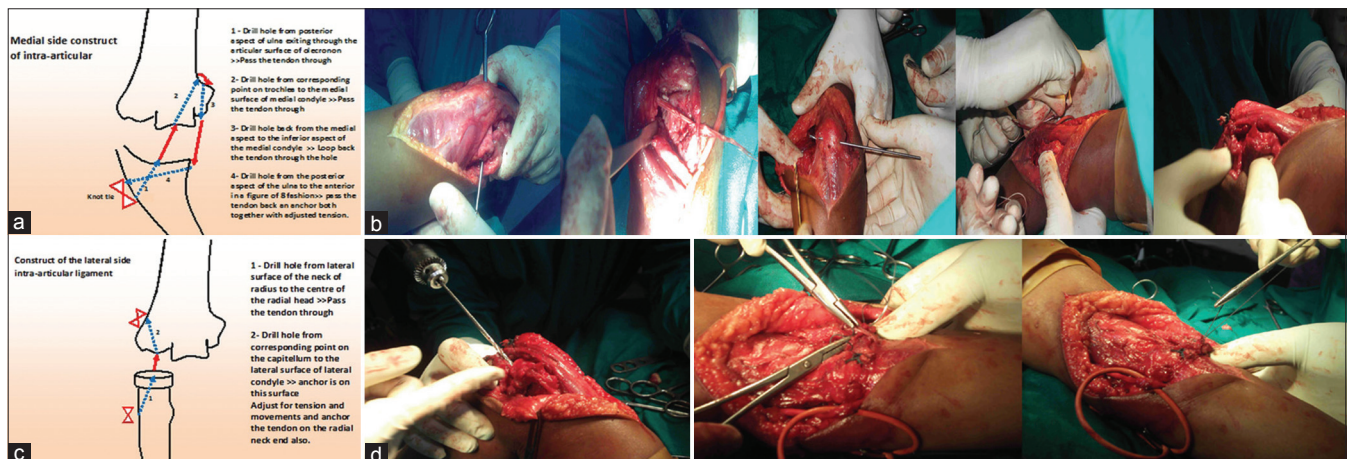
The results were assessed on basis of time of surgery, complications, range of motion achieved, and MEPI.

## Results

The results of both the groups have been stated tabulated [Table 2]. The average time of surgery was significantly less in



**Figure 1A:** (a) Exposure (b) Radio humeral horn - identification and careful excision (c) Reduction achieved without triceplasty



**Figure 1B:** (a) Line diagram depicting the medial side construct (b) The cruciate ulno humeral construct (c) Line diagram depicting lateral construct (d) Lateral ligament construct



Group I (67 mins) as compared to Group II (88 mins). In the post-op period there were two cases in group I (17%), and three cases in Group II (21%) with showed evidence of infection in form of redness, increased temperature, pain, discharge and wound dehiscence. All of them healed uneventfully with regular dressings and antibiotics in 4 weeks. There was also ulnar nerve affection in both groups, two cases in Group I (17%) and two cases in Group II (14%). All four cases recovered without any surgical intervention at 1 year follow-up.

We evaluated the MEPI score at a minimum follow-up of 1 year. Eight out of 12 patients (75%) of Group I had satisfactory outcome (6 excellent, 2 good) while the other four had poor outcome (25%). On the other hand 13 out of 14 patients (93%) had satisfactory outcome in Group II (10 excellent, 3 good) while only one had a poor outcome (7%) ( $P < 0.05$ ). The mean increase in the MEPI score was 36.6 for Group I (range 18–55) while 53.5 for Group II (range 30–64) ( $P < 0.05$ ). On individual component score evaluation, we found that mean increase in pain score was same for both groups (12.5 for each) but the increase in the rest of the three scores for Group II (12.5 for movement, 9 for stability and 19.5 for activities) was significantly more as compared to Group I (6 for movement, 5.5 for stability and 12.5 for activities). The average ROM at 1 year follow-up for Group I was 96° while for Group II was 118°. The average increase in ROM of Group I was 54° (range 15°-96°) while that of Group II was 73.5° (range 45°–100°) ( $P < 0.05$ ). The mean supination/pronation arc for Group I was 130° while that of Group II was 120°. The mean increase in the arc for Group I was 40° while that of Group II was 35°. At 1 year postoperative the average medio lateral instability in Group I was 12° while that of Group II was 8°. None of them had any complaints on the graft harvested site

follow-up. Serial X-rays showed that reduction was maintained in all cases at the end of 2 years. There was radiological subluxation or incongruity of the joint in four cases of Group I (33%) and five cases of Group II (36%). This radiological finding was not evident clinically and did not affect any function. The development of post-traumatic arthritis was evaluated using the Broberg and Morrey score at the 2 year follow-up. Three patients in Group I (25%) and three patients in Group II (21%) had grade I arthrosis, while four patients each in Group I (33%) and two in group II (21%) had Grade II arthrosis. Duration of dislocation directly corresponded to these cases but clinical results did not [Figures 2 and 3].

We separately evaluated these five cases of poor outcome [Table 3] and found that all of these cases were more than 1-year duration of dislocation and age more than 22 years. Also, three out of five had some associated fracture and four out of five had post-operative infection. Two out of five patients were females, which is the same ratio of the overall case presentation. Two out of these five cases (40%) had radiological subluxation which was similar to the mean of 34% of the total cases ( $P > 0.01$ ). Out of these five cases, two cases (40%) had grade I arthrosis and one case (20%) had grade II post-traumatic arthritis which again not significantly more than the total average values. The 1 poor outcome of group II were among the first three cases performed for this procedure. The last 11 cases had no poor outcomes.

## Discussion

Old unreduced elbow dislocations are common in low-income countries due to lack of awareness and poor access to proper

**Table 2: Results**

	Group I - K wire fixation group N=12	Group II - Elbow cruciate ligament reconstruction group N=14	Significance (P value)
Average time of surgery (minutes)	67 (55-82)	88 (60-100)	Significant ( $P < 0.05$ )
Infection	2 (17%)	3 (21%)	Not significant ( $P > 0.05$ )
Ulnar nerve affection	2 (17%)	2 (14%)	Not significant ( $P > 0.05$ )
Average post op ROM (1 year) (degrees)	96	118	Significant ( $P < 0.05$ )
Average increase in ROM (degrees)	54 (15-96)	73.5 (45-100)	Significant ( $P < 0.05$ )
Average post op supination/pronation arc (1 year) (degrees)	130	120	Not significant ( $P > 0.05$ )
Average increase in supination/pronation arc (degrees)	40	35	Not significant ( $P > 0.05$ )
Average post op medio lateral instability (1 year) (degrees)	12	8	Significant ( $P < 0.05$ )
MEPI score satisfactory outcome	8 (75%)	13 (93%)	Significant ( $P < 0.05$ )
Excellent	6	10	
Good	2	3	
Poor	4	1	
Average increase in MEPI score (points)	36.6 (18-55)	53.5 (30-64)	Significant ( $P < 0.05$ )
Pain score	12.5	12.5	
Movement	6	12.5	
Stability	5.5	9	
Activities	12.5	19.5	
Complaints of graft site (knee)	-	None	
Radiological subluxation	4 (33%)	5 (36%)	Not significant ( $P > 0.05$ )
Post-traumatic arthritis (2 years follow up)	Grade I - 3 (25%) Grade II - 4 (33%)	Grade I - 3 (21%) Grade II - 3 (21%)	Not significant ( $P > 0.05$ )

ROM = Range of motion, MEPI = Mayo's elbow performance index

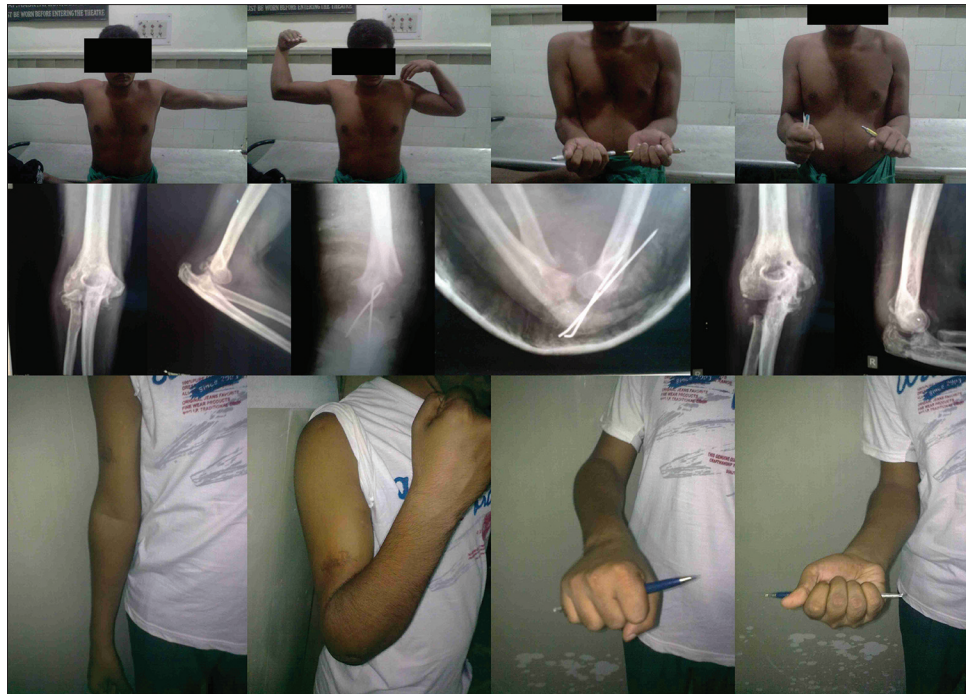

Figure 2: Clinical case of group I

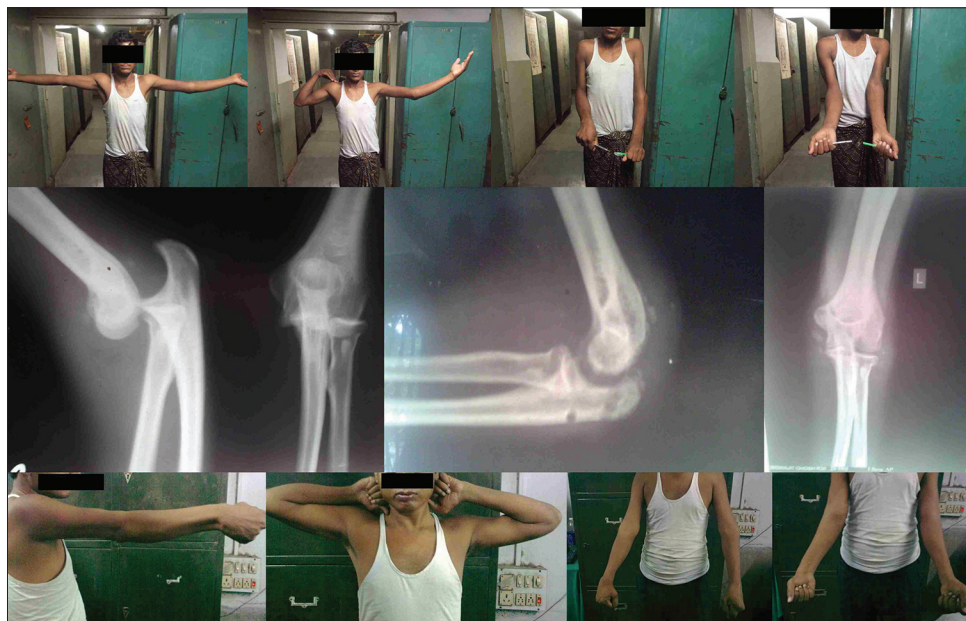

Figure 3: Clinical case of group II

Table 3: Details of the five bad results

	Group I/II	Duration of dislocation (months)	Associated fracture	Age	Sex M/F	Post-operative infection	Radiological Subluxation	Post-traumatic arthritis grade
1	I	22	Lateral condyle	23	M	Yes	Yes	I
2	I	36	None	32	F	No	Yes	II
3	I	14	Olecranon, medial condyle, radial head	36	F	Yes	No	II
4	I	20	None	28	M	Yes	No	0
5*	II	18	Lateral condyle	30	M	Yes	No	I

\*The one case of group II which was in the first 3 to be operated, the last 11 cases had no poor outcomes

medical care.<sup>[1-5]</sup> Some surgeons prefer open reduction of such cases till 3 months but prefer arthroplasty after that.<sup>[8-12]</sup> Others are proponents of open reduction even up to 2–4 years.<sup>[5,6,15,18]</sup> It is very difficult for patients of these economic strata to afford costly elbow prosthesis. Excision arthroplasty is a cheaper option but it leaves an unstable elbow hence condemned.<sup>[10,19]</sup> Lately, there has been interest in gradual reduction of these cases using a hinged external fixator, but it again amounts to increased cost and prolonged morbidity.<sup>[17,20]</sup> Therefore, open reduction seems to be a fair option for these cases.

Speed (1925) introduced the method of triceps lengthening using VY plasty to reduce old dislocations of elbow.<sup>[21]</sup> The same method has been followed by many authors all throughout the century like Billet,<sup>[22]</sup> Naidoo,<sup>[18]</sup> and Fowles.<sup>[23]</sup> The technique essentially consists of extensive release, V–Y plasty and K-wire fixation for 2–4 weeks post-op followed by aggressive physiotherapy. Later on some authors like Krishnamoorthy<sup>[24]</sup> tried reduction without triceplasty using a medial and lateral approach. The same technique has been followed by many others. Mahavaiashya *et al.*,<sup>[25]</sup> performed a comparative study and found better results with the later. However, all of them use K-wire or POP cast immobilization post-operatively for varied amount of time. The only exception being Arafles *et al.*,<sup>[15]</sup> (1987), who have tried to create an interarticular cruciate ligament like structure using palmaris longus of the patient to provide immediate antero-posterior stability to the patient. This could avoid a K-wire fixation and give early movement to the patients (6<sup>th</sup> post-operative day). They showed good results in the 11 cases they operated. The only other study to our knowledge which has used this kind of stabilization is a report of three cases by Majima and Nakamura.<sup>[26]</sup>

In our study, we have made several modifications to this concept. We have used semitendinosus tendon instead of palmaris longus for our series. The operative time was minimized a separate team harvested the tendon graft simultaneously. Also, we found that although this sling is supposed to prevent anterior posterior instability, since it attached to the ulna only it acts more as a antero-medial and postero-medial constraint, leaving the lateral side instable. We found significant instability in the cadaveric studies and also during the operations with only one constrain, especially in extension. We added the step of a lateral sling reconstruction with the left part of the tendon to overcome the problem. This tendon is not a loop, as it is not sutured back to itself, but rather it is anchored on both sides separately. Thus, it behaves like the ligamentum teres of femur head, providing enough stability without preventing any movement restriction (supination, pronation). Also, we did not cut a slot in the trochlea for passage of the tendon as we did not find any incarceration of the tendon during our cadaveric dissections. This also prevented us from destroying an already affected articular surface of the trochlea. All this elaborate cruciate ligament system had only one purpose – early mobilization. Therefore, we advocate active movement on the very next day with good post-operative analgesia, a good physiotherapy team and proper motivational support for the patient. Since, early

active movement was the main goal of our treatment we tried to avoid triceplasty as far as possible and were able to do so in all 26 cases. With extensive release of triceps, sometimes up to the upper-third of humerus and with extensive release of the capsule and excision of radio-humeral horn we were always able to achieve reduction without any triceplasty at all. We found radio-humeral horn in all the patients and we believe it to be a physiological ossification around the fibrosis of the displaced radial head. Since all are cases were more than 3-months old, we believe it as the maximum time it takes to form this horn. It might be inconspicuous in some cases but careful identification and excision of this horn eases the radio capitellar reduction a lot. We also tried to preserve the collateral ligaments and articular cartilage by using sharp blade dissection as close to the bone as possible. We believe that both these factors together were responsible for the excellent results that we have achieved in both the groups. These results are comparable if not better than other studies in recent literature.<sup>[1-7]</sup>

Comparing both groups, it is clear that Group II has definitely fared better in terms of movement, stability and activity performance. We believe that the extra stability provided by the cruciate ligaments helped in giving extra medio-lateral stability, improving the overall stability scores. The immediate stability provided by the ligaments allowed the patient to do immediate movement post-operatively, thereby preventing fibrosis restricting the final ROM. Better ROM and stability together reflected on the better activity score. This average surgery duration for Group II was 21 minutes more than Group I, but this did not reflect in the complication rate or post-operative results. There was also a statistically insignificant increased incidence of radiographic subluxation in Group II but again this did not have any effect on the clinical outcome. On careful evaluation of the five cases of poor outcomes, we confer that age (>40 years), duration of dislocation, associated fractures lead to adverse outcomes while sex, duration of surgery, radiographic subluxation and arthritis did not.

Comparing these results with the results of Aralifes *et al.*,<sup>[15]</sup> our results were better both in term of ROM (118° as compared to 95°) and valgus varus instability (8° as compared to 12°). Arafles *et al.*, have not used any scoring system like MEPI scores which we have used for better and standardised evaluation. We attribute these results to the extra sling on the lateral side, as well as a more aggressive rehabilitation (movement from the first day post-operative as opposed to sixth day post-op). Using semitendinosus instead of Palmaris longus gave us more confidence in our ligament reconstruction, which translated to a more aggressive rehabilitation and better results. Avoiding triceplasty, collateral ligament preservation and articular surface preservation might also be contributing factors. But, since these factors are common to Group I and II we can conclude that the ligament construction with early movement is the main factor which significantly improves the outcome of these patients. We also found that this technique has a steep learning curve. This is evident by the one poor result in the first three patients and none in the last 11.



On the whole we conclude that this new modified technique serves as a good approach for better functional results in old elbow dislocations, especially in socio-economic group that cannot afford the costly hinged ring fixator devices. It is technically demanding operation with a steep learning curve but the time and effort put in the operation surely shows in the results.

## References

- Seth M, Flores M. Management of neglected dislocation of elbow. *Indian J Orthop* 1986;20:177-81.
- Bhattacharya D. Open reduction for old unreduced posterior dislocation of the elbow-a review of results. *Indian J Orthop* 1979;13:34-8.
- Bruce C, Laing P, Dorgan J, Klenerman L. Unreduced dislocation of the elbow: Case report and review of the literature. *J Trauma* 1993;35:962-5.
- Gill S, Dhillon M, Gupta R. Neglected elbow dislocation in children. *Indian J Orthop* 1997;31:193-5.
- Devnani AS. Outcome of longstanding dislocated elbows treated by open reduction and excision of collateral ligaments. *Singapore Med J* 2004;45:14-9.
- Mehta S, Sud A, Tiwari A, Kapoor SK. Open reduction for late-presenting posterior dislocation of the elbow. *J Orthop Surg (Hong Kong)* 2007;15:15-21.
- Srivastava K, Bhattacharyya AN. Dislocation of elbow. *Indian J Orthop* 1969;3:46-54.
- Freeman BL 3<sup>rd</sup>. Old unreduced dislocations. In: Crenshaw AH, editor. *Campbell's Operative Orthopaedics*. 9<sup>th</sup> ed. Vol. 1. St. Louis: Mosby; 1998. p. 2673-4.
- Rockwood CA. Treatment of old unreduced posterior dislocation of elbow. In: Rockwood CA, editor. *Rockwood and Green's Fracture in Adults*. 4<sup>th</sup> ed. Vol. 1. Philadelphia: Lippincot-Raven; 1996. p. 975-6.
- di Schino M, Breda Y, Grimaldi FM, Lorthioir JM, Merrien Y. Surgical treatment of neglected elbow dislocations. Report of 81 cases. *Rev Chir Orthop Reparatrice Appar Mot* 1990;76:303-10.
- Lyons RP, Armstrong A. Chronically unreduced elbow dislocations. *Hand Clin* 2008;24:91-103.
- Ramsey ML, Adams RA, Morrey BF. Instability of the elbow treated with semiconstrained total elbow arthroplasty. *J Bone Joint Surg Am* 1999;81:38-47.
- Baksi DP. Sloppy hinge prosthetic elbow replacement for post-traumatic ankylosis or instability. *J Bone Joint Surg Br* 1998;80:614-9.
- Morrey BF, Adams RA. Semiconstrained arthroplasty for the treatment of rheumatoid arthritis of the elbow. *J Bone Joint Surg Am* 1992;74:479-90.
- Arafles RP. Neglected posterior dislocation of the elbow. A reconstruction operation. *J Bone Joint Surg Br* 1987;69:199-202.
- Broberg MA, Morrey BF. Results of treatment of fracture-dislocations of the elbow. *Clin Orthop Relat Res* 1987;109-19.
- Jupiter JB, Ring D. Treatment of unreduced elbow dislocations with hinged external fixation. *J Bone Joint Surg Am* 2002;84-A: 1630-5.
- Naidoo KS. Unreduced posterior dislocations of the elbow. *J Bone Joint Surg Br* 1982;64:603-6.
- Rubino LJ, Herbenick MA, Finnan RP, Anloague PA. Chronic elbow dislocation treated with open reduction and lateral ulnar collateral ligament reconstruction. *Am J Orthop (Belle Mead NJ)* 2009;38:E98-100.
- Lo CY, Chang YP. Neglected elbow dislocation in a young man: Treatment by open reduction and elbow fixator. *J Shoulder Elbow Surg* 2004;13:101-4.
- Speed JS. An operation for unreduced post dislocation of elbow. *South Med J* 1925;18:193.
- Billett DM. Unreduced posterior dislocation of the elbow. *J Trauma* 1979;19:186-8.
- Fowles JV, Kassab MT, Douik M. Untreated posterior dislocation of the elbow in children. *J Bone Joint Surg Am* 1984;66:921-6.
- Krishnamoorthy S, Bose K, Wong KP. Treatment of old unreduced dislocation of elbow. *Injury* 1976;8:39-42.
- Mahaisavariya B, Laupattarakasem W, Supachutikul A, Taesiri H, Sujaritbudhngkoon S. Late reduction of dislocated elbow. Need triceps be lengthened? *J Bone Joint Surg Br* 1993;75:426-8.
- Majima M, Horii E, Nakamura R. Treatment of chronically dislocated elbows: A report of three cases. *J Shoulder Elbow Surg* 2007;16:e1-4.

How to cite this article: Garg P, Paik S, Sahoo S, Raj V, Pispati A, Mitra S. A new technique for surgical management of old unreduced elbow dislocations: Results and analysis. *J Orthop Allied Sci* 2014;2:45-51.

Source of Support: Nil, Conflict of Interest: None declared.