

Access this article online

Quick Response Code:



Website:

www.joas.org.in

DOI:

10.4103/JOASP.JOASP_25_21

Correction of kyphosis by overcoming the challenge of pedicle screw fixation in previously augmented vertebrae by vertebroplasty

Shailesh Hadgaonkar, Himanshu Gurunath Kulkarni, Askhar Haphiz, Parag Sancheti¹, Ashok Shyam¹

Abstract:

Osteoporotic vertebral compression fractures (OVCF) is one of the most common degenerative spine pathologies that a spine surgeon comes across. Percutaneous cement augmented vertebroplasty or Balloon kyphoplasty are one of the most commonly used treatment modalities for OVCF. Spine surgeons may sometimes encounter situations in which they might need to operate for another spinal pathology, such as degenerative spinal instabilities, spinal infections, and neoplasms, which warrant posterior instrumented stabilization in patients who have already undergone vertebroplasty. Passing pedicle screws in these vertebrae can be very difficult and if these levels are skipped, the span of the fixation may increase and involve more normal levels for the sake of the stability of the construct. We present a case of a 49-year-old male with severe back pain, Cushing's syndrome, and thoracolumbar kyphosis occurring due to multiple osteoporotic fractures, which had been previously treated with vertebroplasties at five levels. With meticulous preoperative planning with CT scans and whole spine X-rays, pedicle screws were passed in vertebrae that had been previously augmented with vertebroplasty. Kyphosis and sagittal balance were completely corrected, and the patient exhibited significant symptomatic improvement. So, we suggest that even though many surgeons feel that the presence of vertebroplasty contraindicates the placement of pedicle screws in the vertebrae previously treated with vertebroplasty, it is feasible with proper preoperative planning.

Keywords:

Balloon kyphoplasty, cement augmented vertebroplasty, progressive kyphosis, sagittal balance

Department of Spine Surgery,
¹Sancheti Institute of Orthopaedics and Rehabilitation, Pune, Maharashtra, India

Address for correspondence:

Dr. Himanshu Gurunath Kulkarni,
Department of Spine Surgery,
Sancheti Institute of Orthopaedics and Rehabilitation, 16, 11/12, Shivajinagar, Thube Park, Pune 411005, Maharashtra, India.
E-mail: hgkulkarni@gmail.com

Received : 18 April 2021

Accepted : 04 February 2022

Published : 23 June 2022

Introduction

Due to the advancements in medicine, enhanced life expectancy is responsible for making spine surgeons face a plethora of degenerative pathologies. Among all the sequelae of degeneration and osteoporosis, osteoporotic vertebral compression fractures (OVCF) can sometimes be a tricky puzzle to solve. These are a leading cause of disability and morbidity in the elderly.^[1] Percutaneous cement augmented vertebroplasty or Balloon kyphoplasty are one of the most

commonly used treatment modalities for OVCF. Spine surgeons may sometimes encounter situations in which they might need to operate for another spinal pathology, such as degenerative spinal instabilities, spinal infections, neoplasms etc., which warrant posterior instrumented stabilization in patients who have already undergone vertebroplasty. Passing pedicle screws in these vertebrae can be very difficult and if these levels are skipped, the span of the fixation may increase and involve more normal levels for the sake of the stability of the construct.^[2] Although a lot has

This is an open access journal, and articles are distributed under the terms of the Creative Commons Attribution-NonCommercial-ShareAlike 4.0 License, which allows others to remix, tweak, and build upon the work non-commercially, as long as appropriate credit is given and the new creations are licensed under the identical terms.

For reprints contact: WKHLRPMedknow_reprints@wolterskluwer.com

How to cite this article: Hadgaonkar S, Kulkarni HG, Haphiz A, Sancheti P, Shyam A. Correction of kyphosis by overcoming the challenge of pedicle screw fixation in previously augmented vertebrae by vertebroplasty. J Orthop Spine 2021;9:90-3.

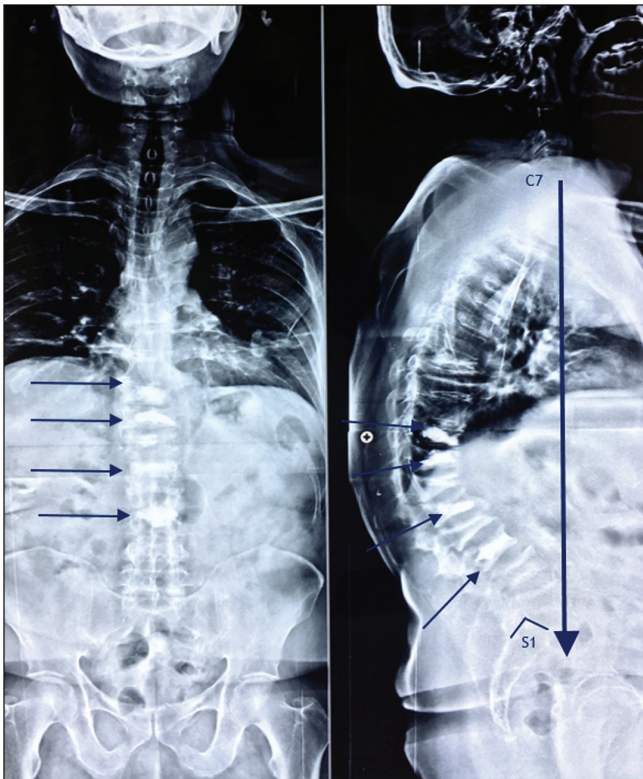


Figure 1: Showing multiple OVCF, positive sagittal balance, and five vertebrae augmented with bone cement

been written about the safety and efficacy of cement-augmented screw fixation for enhanced pull-out strength in osteoporotic vertebrae, very scarce literature is available about the challenges of pedicle screw fixation in vertebrae previously treated with cement augmented vertebroplasty.^[3,4] We present a case of correction of a progressive thoracolumbar kyphosis occurring due to multiple osteoporotic fractures, which had been previously treated with vertebroplasties at five levels.

Case Report

A 49-year-old male presented with severe back pain and deformity of the back since two years. The patient was a known case of Cushing's syndrome and had been operated for an adrenal tumor with adrenalectomy three years earlier. He had also been operated with cement augmented vertebroplasties at multiple vertebral levels elsewhere one year earlier. Even after the procedure, the patient had no symptomatic relief. The VAS score at present was 7 and the Modified Oswestry Disability Index (MODI) was 68.2 on examination. The patient had no loss of power in the lower limbs or loss of bladder/ bowel sensations or any signs suggesting an upper motor lesion. Routine blood investigations showed no significant abnormality. A DXA scan revealed the lumbar T score to be -2.7, which indicated osteoporosis. The X-ray revealed that the patient had multiple osteoporotic fractures, resulting in thoracolumbar kyphosis [Figure 1]. Sagittal

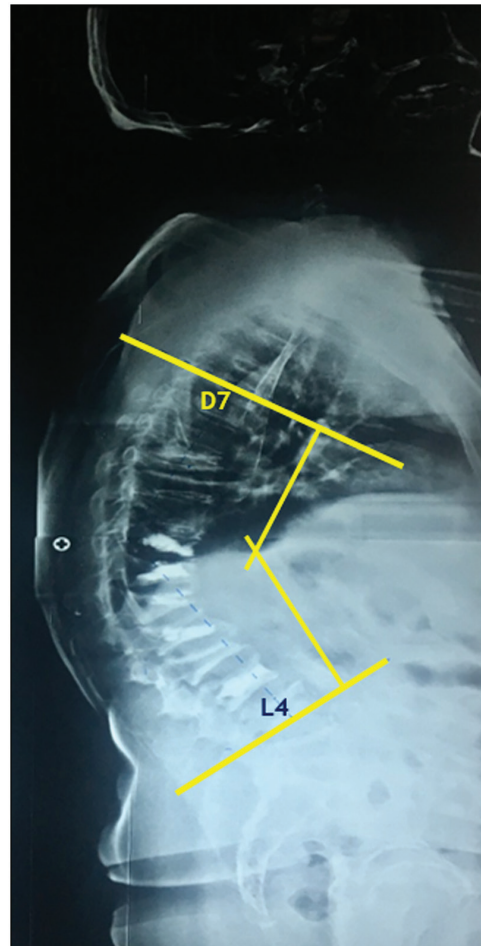


Figure 2: Global kyphosis with K angle of 65°

balance was lost with the plumb line from C7 falling anterior to S1 vertebra. Cement augmentation was done at five levels, D10-11-12 and L1, L3.

The X-ray also revealed global kyphosis from D7 to L4, complete loss of lumbar lordosis with kyphosis angle being 65° [Figure 2].

An MRI showed no significant neurological compromise at any level but revealed a fresh OVCF at D7 level. A CT scan was done for the decision making of the screw placement. The mid-axial cuts of the CT scan were examined, and a decision was taken about the possibility of placing the screws at every level, especially those that had already been augmented with bone cement during the vertebroplasty. The lengths of the screws were decided depending on the space available [Figure 3].

During the procedure via a posterior midline approach, exposure was done from D4 to S2. Pedicle screws were inserted from D4 to S1. An iliac screw was placed from S2 in view of the length of the construct and the osteoporotic bone. Since the cement mantle had occupied almost the complete vertebral body, D11 was omitted from fixation. In other augmented levels, even though the

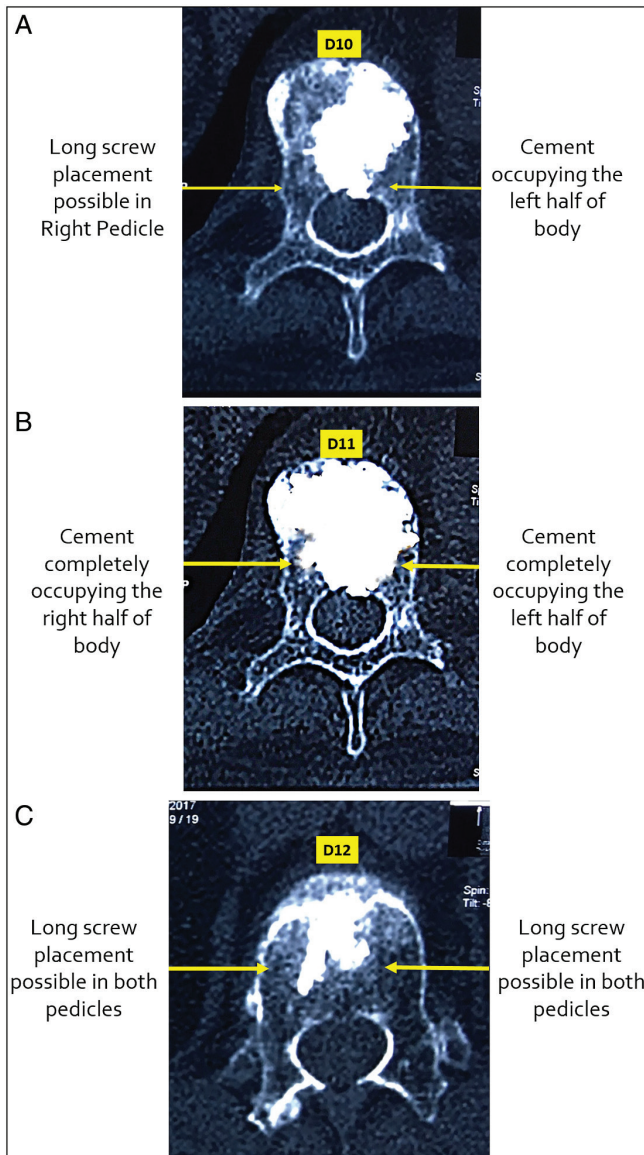


Figure 3: (A) Axial cut of D10 showing relatively empty right half. (B) Axial cut of D11 showing the cement completely occupying the body. (C) Axial cut of D12 showing minimal cement filling in the body

trajectories of screws were not completely ideal, screws were successfully passed, negotiating the cement mantle in the body [Figure 4].

Posterior column osteotomies were done at multiple levels. A well-contoured rod was fixed with the Cantilever technique, correcting the kyphosis. Further correction of kyphosis was done by intersegmental compression, lumbar lordosis was restored with the help of a similar technique, and closure was done. All spinous processes of fixed levels were stopped, and shingling of all laminae was done. Bone graft harvested from all spinous processes was mixed with allograft and was prepared in a bone mill. Copious graft was placed on a prepared posterior bed. Rehabilitation was started with the help of a brace. Since the patient had been previously

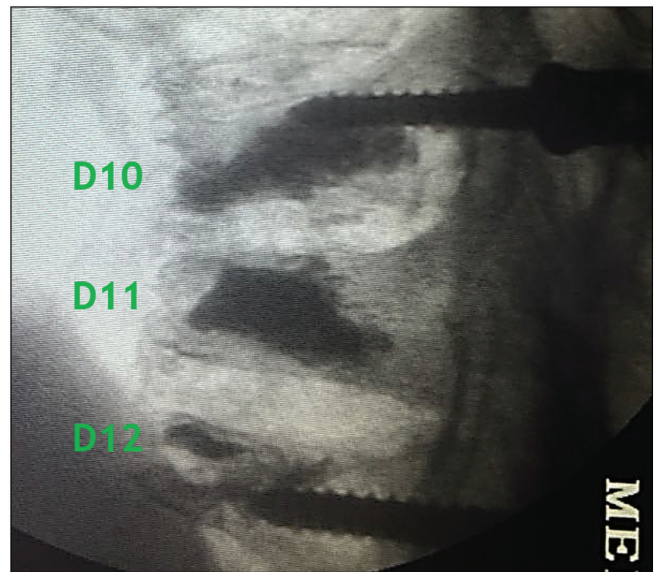


Figure 4: Intraoperative image showing the D10 screw passed superior to the cement mantle

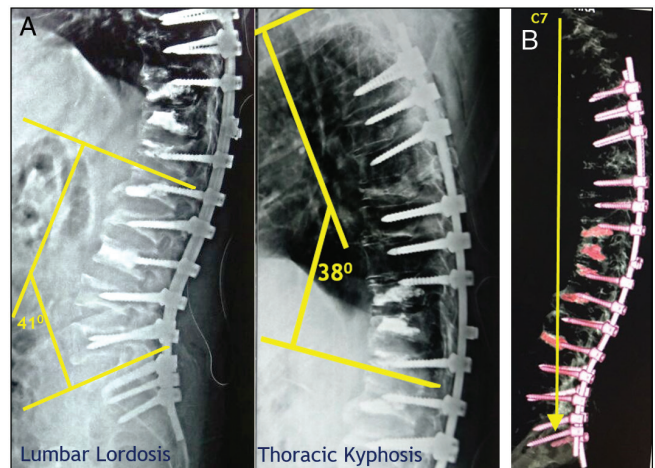


Figure 5: (A) Restoration of normal thoracic kyphosis and lumbar lordosis. (B) Restoration of normal sagittal balance

operated for adrenalectomy, an endocrinologist was consulted and anti-osteoporotic medical treatment was started immediately. Postoperative X-rays revealed that thoracic kyphosis was restored at 38° and lumbar lordosis was restored at 41° [Figure 5A]. Sagittal balance was corrected too [Figure 5B].

At the end of one year, patients' posture and back pain were significantly improved (VAS- 2); MODI improved to 19.5. The patient was able to carry out all the daily activities without any hindrance.

Discussion

Percutaneous cement augmented vertebroplasty is one of the most popular treatment modalities for OVCF.^[5] Due to the minimally invasive nature of vertebroplasty,

the minimal risks involved, and the short hospital stay, its use is widespread. It provides excellent results in the form of pain relief in OVCF Kummel's lesions.^[6] However, once the PMMA cement has been injected, it will remain in the vertebral body for the entire duration of the patient's life unless it is surgically removed. Spine surgeons may sometimes encounter situations in which they might need to operate for another spinal pathology, such as degenerative spinal instabilities, spinal infections of neoplasms etc., which warrant posterior instrumented stabilization in patients who have already undergone vertebroplasty. Inserting pedicle screws in the vertebrae that have already been augmented by bone cement has always been considered very difficult. Many surgeons feel that the presence of vertebroplasty contraindicates the placement of transpedicular instrumentation. Jae Hoo Park *et al.* studied 14 patients who required screw fixation at the level of the previous percutaneous vertebroplasty.^[7] They concluded that for patients with vertebrae previously augmented with bone cement, posterior screw fixation is not a contraindication, but it is a very feasible option. They classified the cement distribution patterns in cement augmented vertebrae on simple radiographs as follows:

- 1) Solid compact cement filling
- 2) Trabecular-type/sponge-like cement filling

They concluded that Type 2 cement fillings can be penetrated by the pedicle screws, which will be unlikely in Type 1 filling patterns.

On a technical note, Joanna Gernsback and Michael Wang presented a technique that involved drilling through the cement mantle in the vertebral body with a cannulated reamer and passing a cannulated pedicle screw in the cement mantle over the guide wire.^[8] We made no such attempt in D11 in which the cement occupied almost the whole body and left no space for the pedicle screw.

CT scans are the mainstay in preoperative planning. The axial cuts of every augmented vertebral level can give the surgeon an exact idea about the cement filling in the vertebral body. The screws can be passed in a trajectory negotiating the cement mantle in the vertebral body. Screw insertion in old, healed non-augmented OVCF can also be tricky because the altered and reduced shape of the body can make it difficult to pass the screw in an ideal trajectory

that is of optimal length. We successfully overcame this with inferiorly directed 45mm screws in L2 and L4.

Conclusion

Although difficult, the placement of pedicle screws in the vertebrae previously treated with vertebroplasty is feasible. Careful preoperative assessment in the form of plain radiographs and a CT scan is extremely helpful. Although the trajectory of the screw may not be ideal, the cement mantle can be successfully bypassed while passing the screws. Care should be taken not to breach the pedicle wall.

Financial support and sponsorship

Nil.

Conflicts of interest

There are no conflicts of interest.

References

1. Schwab F, Lafage V, Boyce R, Skalli W, Farcy JP. Gravity line analysis in adult volunteers: Age-related correlation with spinal parameters, pelvic parameters, and foot position. *Spine (Phila Pa 1976)* 2006;31:E959-67.
2. Ha KY, Kim YH, Chang DG, Son IN, Kim KW, Kim SE. Causes of late revision surgery after bone cement augmentation in osteoporotic vertebral compression fractures. *Asian Spine J* 2013;7:294-300.
3. Jung HJ, Kim SW, Ju CI, Kim SH, Kim HS. Bone cement-augmented short segment fixation with percutaneous screws for thoracolumbar burst fractures accompanied by severe osteoporosis. *J Korean Neurosurg Soc* 2012;52:353-8.
4. Kim HS, Kim SH, Ju CI, Kim SW, Lee SM, Shin H. The role of bone cement augmentation in the treatment of chronic symptomatic osteoporotic compression fracture. *J Korean Neurosurg Soc* 2010;48:490-5.
5. Xiaochun Li M, Min Yao M, Penfei Y, Xiang Qian M. Comparing pain reduction following vertebroplasty and conservative treatment for osteoporotic vertebral compression fractures: A meta-analysis of randomized controlled trials. *Pain Physician* 2013;16:455-64.
6. Chen LH, Lai PL, Chen WJ. Unipedicle percutaneous vertebroplasty for spinal intraosseous vacuum cleft. *Clin Orthop Relat Res* 2005;435:148-53.
7. Park JH, Ju CI, Kim SW. Posterior screw fixation in previously augmented vertebrae with bone cement: Is it inapplicable? *J Korean Neurosurg Soc* 2018;61:114-9.
8. Gernsback JE, Wang MY. Percutaneous pedicle screw placement into a spinal segment previously treated with vertebroplasty. *J Neurosurg Spine* 2016;24:786-91.