

Access this article online
Quick Response Code:

Website: www.joas.org.in
DOI: 10.4103/JOASP. JOASP_38_20

# Clinicopathological Study of Intradural Extramedullary Spinal Tumors in Central Indian Rural Hospital: 6-year Experience

Prasheelkumar Premnarayan Gupta, Anil Vishnu Akulwar<sup>1</sup>,  
Deepak Premnarayan Gupta<sup>2</sup>, Richa P. Goyal<sup>3</sup>

## Abstract:

**BACKGROUND:** Single institutional study of intradural extramedullary (IDEM) based on clinical presentation, location, and histopathological diagnosis.

**AIM:** The aim of this study is to evaluate a single institution-based epidemiology of IDEM spinal tumors in Rural Hospital of Central India.

**MATERIALS AND METHODS:** This study is retrospective observational study from July 2013 to July 2019 in the Department of Neurosurgery, Mahatma Gandhi Institute of Medical Sciences, Sevagram. A total of 27 patients fulfilled the criteria and were included in the study. The case records of the patients were identified and studied for clinical manifestation, neurological examination, and radiological and histopathological diagnosis.

**RESULTS:** Out of total 35 spinal tumors, 27 patients were IDEM tumors (77.14%) with male-to-female ratio of 1:1.07. While spinal nerve sheath tumors were slightly more common in males, meningioma had significant female preponderance. The most common location of spinal tumor was dorsal spine and the most common histopathological type was schwannoma.

**CONCLUSION:** At present, no published study about epidemiology of IDEM tumors in central India is present. This study may provide the clinicopathological profile of various IDEM spinal tumors for our region.

## Keywords:

Intradural extramedullary, meningioma, schwannoma, spinal tumor

## Introduction

Spinal tumor comprises 5%–12% of total tumor of central nervous system.<sup>[1]</sup> Spinal tumor being exceedingly rare occurs with an incidence of 0.77/100,000 in females and 0.70/100,000 in males. Overall incidence of spinal cord tumors was 0.74/100,000 person-years.<sup>[2]</sup> On the contrary, intradural extramedullary (IDEM) tumor consists of 70% of all spine tumors.<sup>[3]</sup> The most common IDEM tumor in Asian country is schwannoma followed by meningioma.<sup>[4-6]</sup> Other less common tumors

are myxopapillary ependymoma, lipoma, dermoid cyst, and arachnoid cyst.<sup>[7]</sup>

Presenting symptom of IDEM depends on the location of tumor and surrounding mass effect.<sup>[3]</sup> IDEM commonly presents with localized pain, which may be radiating to the limbs.<sup>[8]</sup> Usually, pain may be nocturnal. Other symptoms can be sphincter dysfunction, paraparesis, and erectile dysfunction.<sup>[9]</sup>

There is a paucity of literature regarding the IDEM tumors. At present, there are no data reported for the rural population of central India. Various studies conducted worldwide

This is an open access journal, and articles are distributed under the terms of the Creative Commons Attribution-NonCommercial-ShareAlike 4.0 License, which allows others to remix, tweak, and build upon the work non-commercially, as long as appropriate credit is given and the new creations are licensed under the identical terms.

For reprints contact: WKHLRPMedknow\_reprints@wolterskluwer.com

**How to cite this article:** Gupta PP, Akulwar AV, Gupta DP, Goyal RP. Clinicopathological study of intradural extramedullary spinal tumors in central Indian rural hospital: 6-year experience. *J Orthop Spine* 2021;9:43-5.

Departments of  
Neurosurgery, <sup>1</sup>General  
Surgery and <sup>3</sup>Surgery,  
MGIMS, <sup>2</sup>Department  
of Anesthesia, DMIMS,  
Wardha, Maharashtra,  
India

## Address for correspondence:

Dr. Anil Vishnu Akulwar,  
Vivekanand Block, Quarter  
No. 8, KHS Campus,  
MGIMS, Sevagram,  
Wardha, Maharashtra,  
India.  
E-mail: prasheel.gupta@  
gmail.com

Received: 07 July 2020

Revised: 07 August 2020

Accepted: 01 February  
2021

Published: 20 March 2021

reported difference in the incidence of spinal IDEM; moreover, the incidence varies within the same country region wise. Some spine tumors (e.g., meningioma) are more predisposed to obesity, sedentary life, substance abuse, ionizing radiation, etc., which are more common in urban setup. Hence, our study will give the data pertaining to our region. The aim of the study is to report the clinic-pathological data about IDEM spine tumors for rural population of central India.

## Materials and Methods

This is a retrospective study from July 2013 to July 2019 in the Department of Neurosurgery, Mahatma Gandhi Institute of Medical Sciences, Sevagram, Wardha. All the patients of IDEM spinal tumor operated during the abovementioned period, in the department of neurosurgery were included in the study.

A total of 27 patients fulfilled the criteria and were included in the study. The case records of the patients were identified and studied for clinical manifestation, neurological examination, and radiological and histopathological diagnosis. All the patients were operated by standard midline approach with laminectomy depending on the location of tumor. Due to the limited resources and unavailability of intraoperative monitoring device for our rural setup, motor-evoked potential and somatosensory-evoked potential were not performed in any of the case.

## Results

During the study period, 35 patients of spinal tumor were operated, of which 27 patients were IDEM tumors (77.14%). Among 27 IDEM, 13 were male and 14 were female with male-to-female ratio of 1:1.07. The male-to-female ratio for spinal nerve sheath tumors (SNST) was 1.5:1, while in case of meningioma, it was 1:7. Age of the study population varies from 20 to 69 years with average age of 42.22 years. The most common presenting complaint was localized pain or radicular pain, followed by weakness in limb and bladder involvement [Table 1].

The most common location of IDEM tumor was dorsal, followed by lumbar spine and cervical spine [Table 2]. For SNST (schwannoma and neurofibroma) location in cervical, dorsal, and lumbar spine was 13.33%, 46.67%, and 40%, respectively, while in case of meningioma, it was 12.5%, 75%, and 12.5%, respectively.

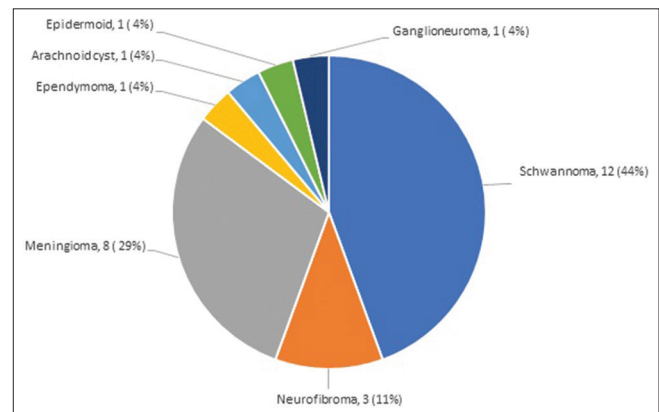
The most common histopathological type was schwannoma, followed by meningioma, neurofibroma, myxopapillary ependymoma, epidermoid, ganglioneuroma, and arachnoid cyst [Figure 1]. The

**Table 1: Presenting symptoms**

Symptoms	n (%)
Pain	26 (96.3)
Weakness	20 (74.07)
Bladder symptoms	6 (22.22)

**Table 2: Location of intradural extramedullary spine tumor**

Location	n (%)
Cervical	4 (14.81)
Dorsal	15 (55.56)
Lumbar	8 (29.63)



**Figure 1: Distribution of various spinal tumors**

most common histopathological type of meningioma was meningotheelial variant (5 cases, 62.5%). Other observed variants were psammomatous (two cases, 25%) and angiomatous (one case, 12.5%).

## Discussion

In our study, IDEM consists of 77.14% of total spinal tumor. It was significantly higher than other studies.<sup>[10-12]</sup> It could be due to selection of more number of IDEM cases as compared to IDIM cases, as there is no facility of intraoperative monitoring in our department.

The most common IDEM tumor in our study was schwannoma accounting for 44.44% of the cases. The overall incidence of SNST (schwannoma and neurofibroma) was 55.56%. Arora *et al.*<sup>[11]</sup> reported twenty cases of SNST (50%) out of total forty IDEM cases. The incidence of nerve sheath tumors was reported as 25% in the series reported by Levy *et al.* and McCormick<sup>[10,13,14]</sup> Levy *et al.* found that males were affected more commonly than females, similar to our study.<sup>[15]</sup> The most common location of SNST was dorsal spine, which corresponds to study done elsewhere.<sup>[10]</sup>

The second most common tumor in our study was meningioma, which was similar to the observation by Bhat *et al.*<sup>[10]</sup> In our study, male-to-female ratio for spinal

meningioma was 1:7, which was similar to Mayo Clinic study and Lakshmi study.<sup>[16,17]</sup> Majority of tumors (75%) were located in thoracic region, which is corresponding with 80% in a series of Mayo Clinic<sup>[17]</sup> and 83% in a study by Roux *et al.*<sup>[18]</sup> The most common histopathological variety observed in our study was meningothelial variant, followed by psammomatous variant. Roux *et al.*<sup>[18]</sup> made similar observation to our study.

## Conclusion

For the study population, we conclude that schwannoma is the most common histopathological variety of IDEM tumor, followed by meningioma. The most common location for IDEM tumor is dorsal spine. Schwannomas are more common in males, while meningiomas are most common in females. Most common presenting complaint is localized pain.

## Financial support and sponsorship

Nil.

## Conflicts of interest

There are no conflicts of interest.

## References

- Newton HB. Overview of spinal cord tumor epidemiology. In: Newton HB, editor. Handbook of Neuro-Oncology Neuroimaging. 2<sup>nd</sup> ed., Ch. 4. San Diego: Academic Press; 2016. p. 35-9.
- Schellinger KA, Propp JM, Villano JL, McCarthy BJ. Descriptive epidemiology of primary spinal cord tumors. *J Neurooncol* 2008;87:173-9.
- Traul DE, Shaffrey ME, Schiff D. Part I: Spinal-cord neoplasms-intradural neoplasms. *Lancet Oncol* 2007;8:35-45.
- Hirano K, Imagama S, Sato K, Kato F, Yukawa Y, Yoshihara H, *et al.* Primary spinal cord tumors: Review of 678 surgically treated patients in Japan. A multicenter study. *Eur Spine J* 2012;21:2019-26.
- Su YF, Lieu AS, Lin CL, Lee KS, Hwang YF, Yen CP, *et al.* Analysis of surgically treated intraspinal tumors in southern Taiwan. *Kaohsiung J Med Sci* 2007;23:573-8.
- Suh YL, Koo H, Kim TS, Chi JG, Park SH, Khang SK, *et al.* Tumors of the central nervous system in Korea: A multicenter study of 3221 cases. *J Neurooncol* 2002;56:251-9.
- el-Mahdy W, Kane PJ, Powell MP, Crockard HA. Spinal intradural tumours: Part I—Extramedullary. *Br J Neurosurg* 1999;13:550-7.
- Song KW, Shin SI, Lee JY, Kim GL, Hyun YS, Park DY. Surgical results of intradural extramedullary tumors. *Clin Orthop Surg* 2009;1:74-80.
- Raco A, Esposito V, Lenzi J, Piccirilli M, Delfini R, Cantore G. Long-term follow-up of intramedullary spinal cord tumors: A series of 202 cases. *Neurosurgery* 2005;56:972-81.
- Bhat AR, Kirmani AR, Wani MA, Bhat MH. Incidence, histopathology, and surgical outcome of tumors of spinal cord, nerve roots, meninges, and vertebral column-Data based on single institutional (Sher-i-Kashmir Institute of Medical Sciences) experience. *J Neurosci Rural Pract* 2016;7:381-91.
- Arora RK, Kumar R. Spinal tumors: Trends from Northern India. *Asian J Neurosurg* 2015;10:291-7.
- Traul DE, Shaffrey ME, Schiff D. Part I: Spinal-cord neoplasms-intradural neoplasms. *The Lancet Oncology* 2007;8:35-45.
- McCormick PC. Surgical management of dumbbell tumors of the cervical spine. *Neurosurgery* 1996;38:294-300.
- Levy WJ, Latchaw J, Hahn JF, Sawhny B, Bay J, Dohn DF. Spinal neurofibromas: A report of 66 cases and a comparison with meningiomas. *Neurosurgery* 1986;18:331-4.
- Levy WJ Jr., Bay J, Dohn D. Spinal cord meningioma. *J Neurosurg* 1982;57:804-12.
- Lakshmi SS. Meningiomas: A clinicopathological study. *Int J Med Res Health Sci* 2015;4:827-37.
- Cohen-Gadol AA, Zikel OM, Koch CA, Scheithauer BW, Krauss WE. Spinal meningiomas in patients younger than 50 years of age: a 21-year experience. *J Neurosurg* 2003;98(3 Suppl):258-63. doi: 10.3171/spi.2003.98.3.0258. PMID: 12691381.
- Roux FX, Nataf F, Pinaudeau M, Borne G, Devaux B, Meder JF. Intradural meningiomas: Review of 54 cases with discussion of poor prognosis factors and modern therapeutic management. *Surg Neurol* 1996;46:458-63.