

Fracture of the trapezoid bone: An unusual fracture

Prashant K. Gupta, Kumkum Gupta¹, Iti Vashisth, Nikhil Rathi

Departments of Radio-diagnosis, Imaging and Interventional Radiology, and ¹Anaesthesiology and Critical Care, Netaji Subhash Chandra Bose Subharti Medical College, Swami Vivekananda Subharti University, Subhartipuram, Meerut, Uttar Pradesh, India

Address for correspondence:

Prof. Prashant K. Gupta,
108, Chanakyapuri, Shastri Nagar, Meerut - 250 004, Uttar Pradesh, India.
E-mail: prashantk.gupta@yahoo.com

ABSTRACT

Isolated fracture of the trapezoid bone is due to axial loading on the outstretched palm and extended wrist, transmitted through the second metacarpal bone. Traumatic lesions of trapezoid bone are rare because of its well-protected position in the wrist and hence missed in the past. The modern diagnostic modalities have made its diagnosis more frequent. The ability of wrist to place the hand in 3-dimensional space is essential for normal daily function of the upper extremity. Some wrist injuries remain a diagnostic enigma, while others remain frustrating to treat either conservatively or with operative intervention. Isolated fractures of the trapezoid bone are rarely reported in the literature. We report a case of an isolated, non-displaced trapezoid bone fracture, which sustained injury by direct trauma and treated conservatively by a cast with return of normal functions.

Keywords: Bone, computerized tomography, fracture, magnetic resonance imaging, trapezoid

Introduction

The trapezoid bone is considered to be the cornerstone of the carpal arch and its wedge shape is perfectly adapted to its role. Strong ligaments connect the trapezoid to the adjacent bones, creating the monolith of the distal carpal bone. Because of its protected position, a direct impact can cause an isolated fracture. However, an axial or bending flexion force acting over the second metacarpal is more often the causative factor.^[1,2]

Case Report

A 23-year-old man with complaint of pain and swelling at the right wrist joint, causing limitation of movements, was referred for radiograph of wrist joint. He sustained the injury after hitting a ball with clenched fist of his right hand. The impact was located over the second-third carpo-metacarpal joint. His neurovascular status was intact. On examination, the tenderness was localized to the radial aspect of the distal carpus but no pain was elicited on palpation of the metacarpal shafts or bases, or distal radius

Access this article online	
Quick response code	Website: www.joas.in
	DOI: 10.4103/2319-2585.152142

or ulna. The initial radiograph of wrist in different views showed no obvious fractures or any sign of trauma [Figures 1 and 2]. However since pain was not relieved after radiography, an initial magnetic resonance imaging (MRI) for the wrist was advised to rule out any soft tissue injury to the of wrist joint, which was negative [Figure 3].

Since clinical suspicion of a hidden carpal fracture was high and in the setting of negative radiographs and MRI, a computed tomography (CT) scan of the wrist was obtained. The CT scan demonstrated a non-displaced fracture of the trapezoid with fracture lines shown in axial plane [Figure 4]. There was no evidence of fracture of any other carpal bones of the hand. His right thumb and wrist was immobilized in a short arm cast. Analgesics and non-steroidal anti-inflammatory drugs was advised to relieve the pain and inflammation. At the most recent follow up examination, he had no complaints and radiographs demonstrated no fracture displacement or bony collapse. The patient had normal pain free range of movement and normal working ability of right hand in follow up.

Discussion

Fractures of carpus most commonly involve the scaphoid with typical physical examination finding of snuffbox tenderness due to fall on the outstretched hand. The hand and forearm fractures are accounted for 1.5% of all traumas. The radius and ulna fractures are the most common (44%) while only 14% of all hand fractures are carpal bone fractures. Trapezoid fractures are rare, encompassing 0.2% of all carpal fractures. The low

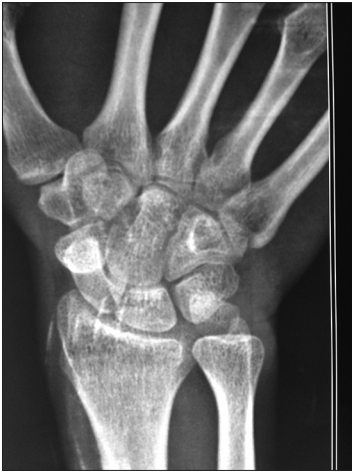

Figure 1: Right wrist Joint A-P view

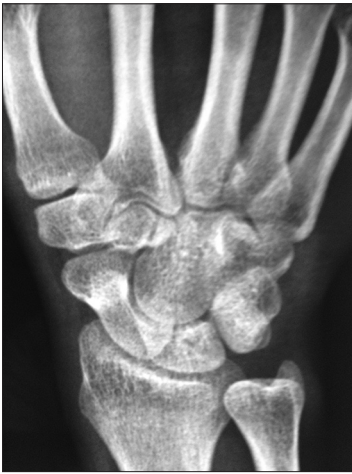

Figure 2: Right wrist joint oblique view

incidence of isolated trapezoid fractures is due to its relatively protected position within the carpus, with both osseous and strong ligamentous stabilizers.

The trapezoid is wedge-shaped and its facet articulates with the second metacarpal distally. In some cases, an additional facet may articulate with the third metacarpal. The radial surface articulates with the trapezium, the ulnar surface articulates with the capitate and the proximal concave surface articulates with the distal scaphoid. The palmar and dorsal aspects receive ligamentous attachments.

Initial diagnosis of this fracture relies on clinical suspicion that is based on complaints and the described mechanism of injury. The proposed mechanism is transfer of energy to the trapezoid through the second metacarpal shaft either axially or through a bending force. Pruzansky *et al.*, reported that this fracture could also result from a blow to the base of the metacarpal.^[3]

Radiographic examination is essential for diagnosis and classification of all carpal fractures and dislocations. All wrist

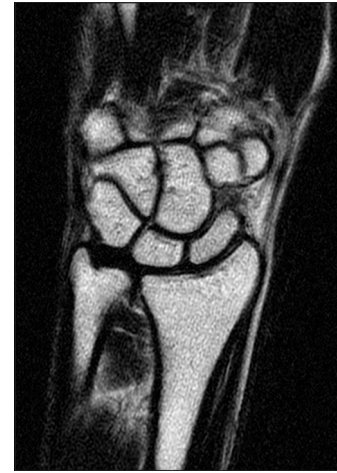

Figure 3: MRI Cor T2 FSE of right wrist joint

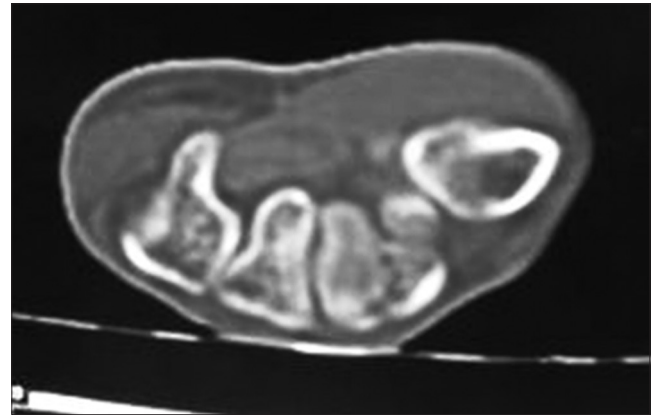


Figure 4: CT axial scan of Right wrist joint showing fracture of Trapezoid bone

injuries initially should include standard antero-posterior (AP), lateral, and supinated and pronated oblique radiographs to visualize the osseous structures of the wrist. Improper positioning of the wrist for radiographs is a common cause of failure to make the correct diagnosis. In addition, all wrist injuries should have scaphoid/navicular views because of the relative frequency of scaphoid fracture. It is likely that an isolated trapezoid fracture will be missed on plain films, especially with non-displaced fractures.

Most wrist fractures and dislocations occur due to fall on outstretched hand (FOOSH) causing axial loading on the outstretched palm and extended wrist, usually during motor vehicle accident, or sports contact injury, resulting in fractures of distal radius, scaphoid, and other carpal bones. These trans-carpal injuries result from extreme hyperextension of the wrist. The position of the wrist and the magnitude and direction of the fall or impact determine the fracture/dislocation pattern. These injuries occur more commonly in young, active, and energetic males but are also common in osteoporotic elderly persons. The overall incidences of these fractures are increasing over time.

The trapezoid fracture is rare and standard radiographs often fail to demonstrate trapezoid fracture. It may be associated with fracture dislocation involving dislocation of the index metacarpal or the trapezoid itself. The force is usually axial along the second metacarpal bone. Most often, these forces result in dorsal dislocation of the trapezoid. Jeong *et al.*, reported on a 31-year-old man who sustained the fracture while throwing a punch^[4] and Miyawaki *et al.* reported a fracture in a 40-year-old man who fell on his right hand in palmer flexion while walking.^[5]

Diagnosis of trapezoid fracture could not be made on initial radiograph of wrist joint neither in our case nor in other reported cases and even an initially advised MRI scan was negative for any obvious fracture. Previous authors have used CT scans, MRI and technetium bone scans to diagnose this fracture. Nijis *et al.*, presented two cases of isolated trapezoid fractures that were diagnosed by MRI and CT scan, in the setting of continued radial sided wrist pain after the initial trauma. They recommended liberal use of imaging studies to diagnose these fractures.^[6] In our patient, CT scan was done to evaluate the painful wrist joint after trauma. Although technetium bone scans are used to diagnose occult trapezoid fractures, we agree with Watanabe *et al.*,^[7] and Groves *et al.*,^[8] that this technique is highly sensitive, interpreter-dependent and invasive with poor resolution. We feel that CT and MRI scans are less invasive and readily available for the diagnosis.

Our patient presented with an isolated trapezoid fracture due to direct blow to the carpus. After conservative treatment by cast immobilization, the complete function of wrist joint was recovered without residual effects.

Conclusion

The use of imaging modalities has increased the detection of occult fractures and ligamentous injuries of the wrist and hand. Isolated trapezoid fractures will continue to remain uncommon entities unless high clinical suspicion is aroused on the basis of the reported mechanism of injury and physical findings, and CT examination can give a positive diagnosis for any bony pathology, especially fractures.

References

1. Garcia Elias M. Carpel bone fractures (excluding scaphoid fractures). In: Watson K, Weinzweig J, editors. The Wrist. 1st ed, Vol 1 Philadelphia: Lippincott Williams and Wilkins; 2001. p. 173-86.
2. Nagumo A, Toh S, Tsubo K, Ishibashi Y, Sasaki T. An occult fracture of the trapezoid bone: A case report. J Bone Joint Surg Am 2002;84-A: 1025-7.
3. Pruzansky M, Arnold L. Delayed union of fractures of the trapezoid and body of the hamate. Orthop Rev 1987;16:624-8.
4. Jeong GK, Kram D, Lester B. Isolated fracture of the trapezoid. Am J Orthop (Belle Mead NJ) 2001;30:228-30.
5. Miyawaki T, Kobayashi M, Matsuura S, Yanagawa H, Imai T, Kurihara K. Trapezoid bone fracture. Ann Plast Surg 2000;44: 444-6.
6. Nijis S, Mulier T, Broos P. Occult fracture of the trapezoid bone: A report on two cases. Acta Orthop Belg 2004;70:177-9.
7. Watanabe H, Hamada Y, Yamamoto Y. A case of old trapezoid fracture. Arch Orthop Trauma Surg 1999;119:356-7.
8. Groves AM, Cheow H, Balan K, Courtney H, Bearcroft P, Dixon A. 16-MDCT in the detection of occult wrist fractures: A comparison with skeletal scintigraphy. AJR Am J Roentgenol 2005;184:1470-4.

How to cite this article: Gupta PK, Gupta K, Vashisth I, Rathi N. Fracture of the trapezoid bone: An unusual fracture. J Orthop Allied Sci 2015;3:28-30.

Source of Support: Nil, Conflict of Interest: None declared.