

## Polyarticular septic arthritis after total joint arthroplasty

Mohan K. Puttaswamy, Raju Sivashanmugam<sup>1</sup>, Matthew J. Phillips<sup>2</sup>

Department of Orthopedics, People Education Society, Institute of Medical Sciences and Research, Kuppam, Andhra Pradesh, India, <sup>1</sup>Fellow in Adult Reconstruction Orthopedics, <sup>2</sup>Department of Orthopedics, UB School of Medicine, Buffalo General Hospital, Buffalo, New York, USA

### Address for correspondence:

Dr. Mohan K. Puttaswamy,  
PES Institute of Medical Sciences and Research, Kuppam - 517 425, Andhra Pradesh, India.  
E-mail: mohanortho@gmail.com

### ABSTRACT

Multiple joint replacements have been employed to treat joint problems in patients with Rheumatoid Arthritis (RA) and is frequently used to address Osteoarthritis too. Septic Arthritis after Arthroplasty is a difficult clinical problem. Polyarticular Septic Arthritis (PASA) in this patient population is an emerging and extremely difficult entity to manage. We describe two patients of RA with PASA and our line of management for this condition. Early recognition and appropriate intervention should help prevent catastrophic outcomes in these unfortunate patients.

**Keywords:** Arthrotomy and debridement, poly articular septic arthritis, rheumatoid arthritis, total joint arthroplasty


### Introduction

Polyarticular septic arthritis (PASA) is simultaneous infection in multiple joints. We present two cases of PASA in patients with rheumatoid arthritis (RA) who were both being treated with immunosuppressive agents and corticosteroids. This is an emerging clinical problem with decreasing age of patient population undergoing arthroplasty, multiple joint replacements and aggressive immunosuppression in inflammatory joint disorders. These cases highlight the difficulties in the diagnoses and management of these potentially fatal conditions.

### Case Reports

#### Case 1

A 50-year-old female patient who is a known case of Rheumatoid Arthritis (RA) on infliximab, methotrexate and prednisolone presented with complaints of pain for 11 days in both her shoulders and knees. The patient had been diagnosed elsewhere

Access this article online	
Quick response code	Website: www.joas.in
	DOI: 10.4103/2319-2585.152145

with a flare of RA and was treated symptomatically for 2 days with no resolution of symptoms. The patient had undergone bilateral total knee arthroplasty (TKA), 14 years ago. On presentation to us, the patient had fever and constitutional symptoms correlating with inflammatory illness. On examination, she had warmth in both knees with significant effusion and range of movement of 10-30° bilaterally. The native shoulder joints had moderate tenderness but had 100° of abduction and 90° of flexion on both sides. In view of the suspicion for infection, we tapped both her shoulders and knee joints. All four aspirates grew methicillin sensitive *Staphylococcus aureus* (MSSA). The patient was started on IV oxacillin 2 gm IV q4 hours. Both her shoulder joints were debrided arthroscopically; her knees were treated with two-stage debridement and re-implantation. In each of her knees implant removal, debridement and articulating spacer surgery was done [Figure 1], IV antibiotic was administered through peripherally inserted central catheter (PICC) line; 12 weeks after initial treatment, the patient underwent bilateral revision TKA with Posterior Stabilized (PS) inserts [Figure 2]. During the revision arthroplasties, we used tobramycin simplex P bone cement into which one gram of vancomycin was added into each batch of cement. The patient is currently infection free after 23 months of revision surgery.

#### Case 2

A 60-year-old Caucasian female patient with RA since the age of 23 on treatment with abatacept, methotrexate and

prednisolone presented with complaints of bilateral hip, knee and back pain for 2 weeks duration. The patient had undergone bilateral (B/L) TKA and total hip arthroplasty (THA), 15 years ago with revision of both knee joints previously for polyethylene wear. The patient's index presentation at another institution was with right knee joint pain for which her rheumatologist started her on prednisolone for a presumptive diagnosis of disease flare. The patient had transient improvement for 3 days with rapid worsening of her general condition. Both her knee joints were swollen with fixed flexion deformities of 10°. The patient showed signs of systemic toxicity for which she was admitted into Intensive Care Unit and treated for septic syndrome. Her blood cultures as well arthrocentesis of both her knee and hip joints grew Methicillin Resistant Staphylococcal Aureus (MRSA). In view of the patient's general medical condition the impact of revising all four joints was discussed with the patient and her family. The decision was made to proceed with joint debridement, polyethylene exchange and IV antibiotic administration. We staged the treatment over three days with hips on consecutive days and knees, simultaneously. We used dilute betadine and hydrogen peroxide during our joint lavage, for 20 minutes, before thorough wash out of the joint with antibiotic saline, which contained gentamycin. Finally, her treatment consisted of open debridement, lavage with bactericidal solution and exchange of all modular components. Her antibiotic regime consists of IV vancomycin through PICC line for 3 months and oral rifampicin for long-term suppression. The patient is currently doing well, 4 months after the surgery and is asymptomatic in her hips and knees.

## Discussion

The two patients are presented to highlight the problems of PASA in RA, after total joint arthroplasty. Both the patients were not diagnosed for 2 weeks after onset of symptoms as it clinically mimicked disease flare. In fact, the patient in Case II was treated with steroids before the diagnosis of infection. The

usual inflammatory markers used for the diagnosis of infection are usually elevated in RA. In Figure 3 points 4-10 represent the infection episode in Case-I and in Figure 4 the points 5-11 indicate the infection episode in case 2. The graphs indicate the consistent elevation of ESR in patients with RA over the normal baseline even without infection.

PASA has been infrequently described in RA. In a large series of 25 patients with PASA and review of literature Dubost<sup>[1]</sup> et al., found that patients having long standing RA (>10 years) and on steroids were susceptible for this condition. They found that blood cultures were positive in 86% of cases and thus they hypothesized that the positive blood culture indicates hematogenous seeding. *Staphylococcus aureus* was grown in 80% of their patients. The mortality in their series was 32% and in the review of literature, ranging from 1950-1990, they showed a consistent mortality rate of around 30%. Patients who are on treatment with anti-tumor necrosis factor (TNF) drugs are also more susceptible for infection like that of the respiratory tract or reactivation of tuberculosis (TB).<sup>[2,3]</sup>

RA patients with infection in multiple replaced joints are a diagnostic as well as therapeutic challenge. The tendency for a delay in management, working diagnosis of disease flare in these patients is a potential threat, which can vitiate the outcome. In both of our patients, there was a mean delay of 2 weeks before a definitive diagnosis of infection was made. This delay potentially precludes the single stage treatment option of thorough lavage, modular exchange and retention of the implant although we chose that option in case II. In that case, our patient's inability

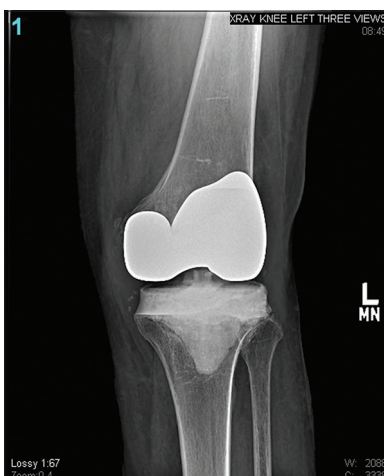


Figure 1: Left knee with antibiotic spacer after the debridement and spacer surgery

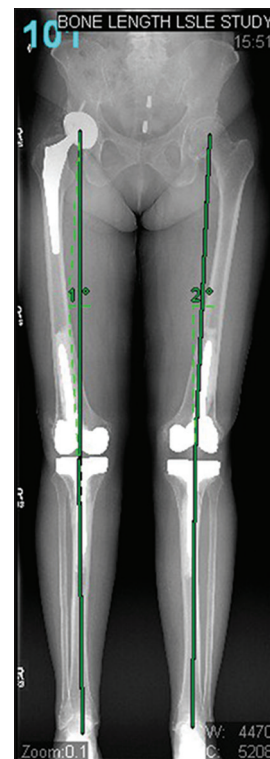


Figure 2: Final outcome after infection eradication

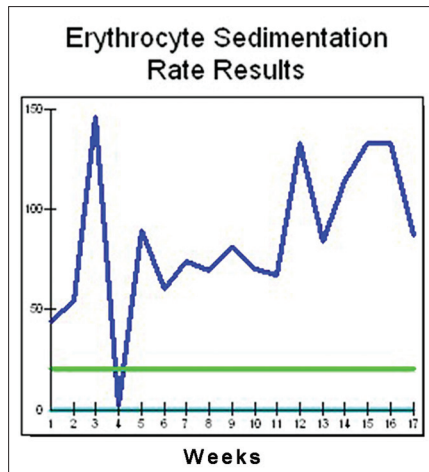


Figure 3: ESR trend in case-1

to withstand an extensive set of revision surgeries in both her hips and knees led us to choose that option as a life-saving set of procedures. In a review of septic arthritis in RA Abdulaziz Al-ahiadeb<sup>(4)</sup> concluded that microscopic analysis and synovial culture form the corner stone in the diagnosis of infection in RA. RA patients can have an elevated ESR, leukocytosis, C-reactive protein (CRP) and other inflammatory markers as part of the disease process.

RA patients who have artificial joints, and who are on potent anti-inflammatory drugs like steroids or anti-TNF alpha drugs, should be counseled regarding the potential possibility of infection and to seek early surgical care, should the symptoms develop. A high index of suspicion on the members of the patient care team, early aspiration and culture, aggressive surgical therapy with debridement of all the infected joints can help rehabilitate the patient.

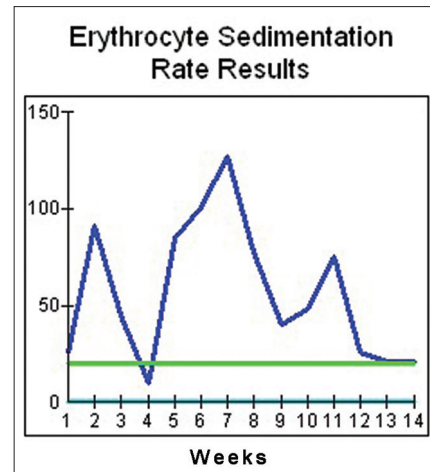


Figure 4: ESR trend in case-2

## References

1. Dubost JJ, Fis I, Lopitoux R, Soubrier M, Ristori JM, Bussiere JL, et al. Polyarticular septic arthritis. *Medicine (Baltimore)* 1993;72:296-310.
2. Fleischmann R, Iqbal I, Nandeshwar P, Quiceno A. Safety and efficacy of disease-modifying anti-rheumatic agents: Focus on the benefits and risks of etanercept. *Drug Saf* 2002;25:173-97.
3. Keane J, Gershon S, Wise RP, Mirabile-Levens E, Kasznica J, Schwieterman WD, et al. Tuberculosis associated with infliximab, a tumor necrosis factor alpha-neutralizing agent. *N Engl J Med* 2001;345:1098-104.
4. Al-Ahaidib A. Septic arthritis in patients with rheumatoid arthritis. *J Orthop Surg Res* 2008;3:33.

How to cite this article: Puttaswamy MK, Sivashanmugam R, Phillips MJ. Polyarticular septic arthritis after total joint arthroplasty. *J Orthop Allied Sci* 2015;3:22-4.

Source of Support: Nil, Conflict of Interest: None declared.

## Staying in touch with the journal

### 1) Table of Contents (TOC) email alert

Receive an email alert containing the TOC when a new complete issue of the journal is made available online. To register for TOC alerts go to [www.joas.in/signup.asp](http://www.joas.in/signup.asp).

### 2) RSS feeds

Really Simple Syndication (RSS) helps you to get alerts on new publication right on your desktop without going to the journal's website. You need a software (e.g. RSSReader, Feed Demon, FeedReader, My Yahoo!, NewsGator and NewzCrawler) to get advantage of this tool. RSS feeds can also be read through FireFox or Microsoft Outlook 2007. Once any of these small (and mostly free) software is installed, add [www.joas.in/rssfeed.asp](http://www.joas.in/rssfeed.asp) as one of the feeds.